

A study of progress of labour using intrapartum translabial ultrasound, assessing head station, direction, and angle of descent

B Tutschek,^{a,b} T Braun,^c F Chantraine,^d W Henrich^c

^a Obstetrics and Gynaecology, University Hospital, Bern, Switzerland ^b Obstetrics, Medical Faculty, Heinrich Heine University, Düsseldorf, Germany ^c Charité Campus Virchow, University Hospital, Berlin, Germany ^d Obstetrics and Gynaecology, University Hospital, Liège, Belgium

Correspondence: Dr B Tutschek, Universitäts-Frauenklinik, Effingerstr. 102, 3010 Bern, Switzerland. Email tutschek@uni-duesseldorf.de

Accepted 27 September 2010. Published Online 18 November 2010.

Objective Intrapartum translabial ultrasound (ITU) has the potential to objectively and quantitatively assess the progress of labour. The relationships between the different ITU parameters and their development during normal term labour have not been studied.

Design Observational study.

Setting University teaching hospital.

Population Labouring women with normal term fetuses in cephalic presentation.

Methods Intrapartum translabial ultrasound measurements for 'head station', 'head direction', and 'angle of descent' (AoD) were taken in 50 labouring women, compared, studied for repeatability, and correlated with the progress of labour.

Main outcome measures Reproducibility and correlation of ITU parameters and their pattern of changes during labour.

Results All three ITU parameters were clinically well reproducible. AoD and head station were interchangeable, and could be calculated from each other. Head station and head direction changed in a typical pattern along the birth canal. Time to delivery correlated with ITU head station.

Conclusions Intrapartum translabial ultrasound is a simple technique that improves the understanding of normal and abnormal labour, enables the objective measurement of birth progress and provides a more scientific basis for assessing labour.

Keywords Angle of descent, angle of progression, head direction, head station, infrapubic line.

Please cite this paper as: Tutschek B, Braun T, Chantraine F, Henrich W. A study of progress of labour using intrapartum translabial ultrasound, assessing head station, direction, and angle of descent. BJOG 2010; Doi: 10.1111/j.1471-0528.2010.02775.x.

Introduction

Intrapartum translabial ultrasound (ITU) has recently been used to study the progress of labour and to predict vaginal delivery,^{1–7} but the correlations of the different parameters, their changes during contractions and pushing, and their development during normal term labour have not been studied comprehensively.

We measured ITU parameters in labouring women with term fetuses in cephalic presentation to determine birth progress objectively. We studied repeatability, compared all ITU parameters, and describe birth mechanics as seen by ITU. As secondary objectives we correlated ITU with time to delivery, and compared ITU-measured head station with digital vaginal examination.

Methods

Data acquisition

Intrapartum translabial ultrasound was performed as described previously.² Using translabial insonation with a 4–8-MHz curved array transducer, dynamic sequences showing a longitudinal midsection of the pubic symphysis and the fetal skull were recorded (positioning of the probe and anatomic landmarks are depicted in Figure 1). Care was taken to align the ultrasound beam in an exact mid-sagittal orientation, and to include the whole length of the pubic symphysis that serves as the reference axis for head direction. Video sequences were recorded digitally, starting from resting and, during a naturally occurring contraction, encompassing one voluntary pushing

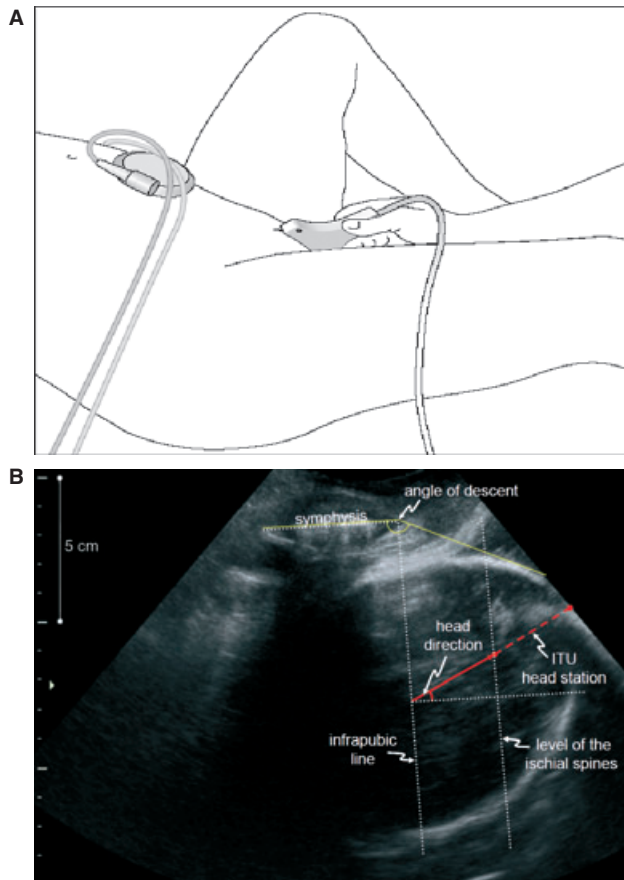


Figure 1. Intrapartum translabial ultrasound (ITU). (A) Placement of the transducer. (B) Typical image with annotated ITU parameters. Mid-sagittal translabial ultrasound shows the fetal head in relation to the long axis and lower margin of the pubic symphysis. The infrapubic line is perpendicular to the long axis of the pubic symphysis. The parallel plane through the ischial spines is 3 cm below the infrapubic line, and is used to measure true head station ('ITU station'). 'Head direction' (degrees upwards or downwards with regard to the long axis of the symphysis) and the 'angle of descent' (tangent to the fetal skull from the lower margin of the pubic symphysis) are the other two quantitative parameters.

sequence. Clinical variables, including patient characteristics, use of epidural analgesia and oxytocin, the results of the vaginal examinations, mode of delivery, and the time interval to delivery were recorded. ITU was not performed in emergency situations. The Institutional Review Board approved the study. Informed consent was obtained from every woman.

Labouring women

In a prospective observational fashion, 50 pregnant women with normal singleton term pregnancies, mostly in the second stage of normal spontaneous labour, were included.

Intrapartum translabial ultrasound was always performed by one of the authors (experienced in general obstetrics

and in fetal–maternal ultrasound), and was performed before the vaginal examination. Then, the managing obstetrician or midwife, who was blinded to the results of the ITU, performed the vaginal exam. The results of the vaginal examinations, taken both in the absence of contraction or voluntary pushing and at the height of pushing, were expressed in cm in relation to the level of the ischial spines (station 0 cm).⁸

Video analysis and measurements

The video sequences were digitised and analysed offline, frame by frame. For each fetus one representative image was selected for 'resting' and for 'pushing' measurements. Exemplary video sequences showing head descent and change in head direction and rotation were generated. In each key image, the 'infrapubic line' was placed perpendicular to the long axis of the pubic symphysis (Figure 1). The plane indicated by the infrapubic line is 3 cm cranial to a parallel plane passing through the ischial spines.^{2,9} The direction of the longest visible axis of the fetal head was measured with regard to the long axis of the symphysis and defined as 'head direction', where positive angles correspond to upward directions and negative angles correspond to downward directions. The sonographically measured head station, 'ITU station', was measured along the longest visible axis of the fetal head, between the intersections with the infrapubic line and the deepest bony part of the fetal head, subtracting 3 cm for the level of the ischial spines. The 'angle of descent' (AoD or 'angle of progression') between the symphysis and the tangent of the fetal skull was also measured (Figure 1).^{4,6}

Data analysis

Twenty different images were randomly selected and measured twice by one operator (on the second occasion blinded to the results of the first measurements), and then again by another independent operator (blinded to the results of the first operator).

Correlations between numerical values were first examined in x – y plots. To assess reproducibility, Bland–Altman plots with 95% intervals of agreement were generated for ITU station, head direction, and AoD.^{10,11} Mean changes in ITU station and head direction during pushing at different stations were tabulated. Correlations between the ITU parameters, and between ITU and time to delivery and digital vaginal examination were analysed. Statistical analysis was performed using a commercial package (SPSS v16.01; SPSS Inc., Chicago, IL, USA). Data were first tested for normality and equal variance (Kolmogorov–Smirnov test). The relation between parameters was assessed by best curve fit, and the desired power for the performed test was accepted for $\alpha > 0.8$.

Results

Maternal, fetal, and birth characteristics are shown in Table 1. Full cervical dilatation was present in 37 of 50 women. Forty-seven fetuses were in occipitoanterior (o.a.) position. There were 28 normal, 13 attempted and successful instrumental, and nine caesarean deliveries.

Repeatability of ITU measurements

There was good repeatability for ITU head station, AoD, and head direction, both for the same and for two different examiners. Intra-observer 95% limits of agreement were ± 1.0 cm for ITU station, $\pm 13^\circ$ for head direction, and $\pm 8^\circ$ for AoD. For interobserver variability, the 95% limits were ± 1.6 cm for ITU station, $\pm 14^\circ$ for head direction, and $\pm 14^\circ$ for AoD (Figure 2). Intraclass correlation coefficients are given in Table 2.

Correlation of ITU parameters

The correlation of ITU station and AoD were studied, both at rest and during pushing. There was a strong linear correlation ($r^2 = 0.90$, $P < 0.001$; Figure S1), allowing for simple approximate conversions between the two parameters (Table 3) with the following equation, derived by regression from ITU station over AoD: ITU head station (in cm) = AoD (in degrees) $\times 0.0937 - 10.911$. The correlation was almost identical when measurements obtained at rest

and during pushing were analysed separately (data not shown). Further analyses of descent are shown only with regard to ITU station.

The mechanics of labour from cephalic presentation

The changes of ITU-measured head station and head direction during a contraction with pushing differed with head station (Table 4): at stations between -3 and -2 cm, the average descent during a contraction was 2.5 cm, between -2 and $+2$ cm it was 1 cm, and at stations between $+2$ and $+3$ cm it was 2.2 cm. In the upper part of the birth canal and down to head station $+2$ cm, head directions varied, but mostly changed from down to horizontal (Video Clip S1). The average change of head direction during a contraction per 1 cm of head descent overall was $+10^\circ$, but between head station $+2$ and $+3$ cm there was a markedly increased change of head direction during a contraction (on average $+18^\circ$; Video Clip S2).

There were three deliveries from occipitoposterior (o.p.) position (with ITU measured head station at cervical dilatations of 8, 10, and 10 cm, respectively): at ITU head stations of -0.5 , $+1.4$, and $+2.7$ cm, the resting and pushing head directions were -16° , -9° , and 5° . In contrast, for fetuses in o.a. position average head directions at similar head stations (from 0.5 cm above to 0.5 cm below these three stations) were 0° , $+9^\circ$, and $+30^\circ$.

Intrapartum translabial ultrasound and mode of and time to delivery

Advanced ITU head station, upward direction of the fetal head, and high angles of descent (Table 5) were associated with an increasing chance of vaginal delivery (Figure 3).

Among the vaginal deliveries the time to delivery correlates significantly, but weakly, with ITU station ($P < 0.001$, $r^2 = 0.36$; Figure 4). For an ITU station higher than or equal to $+2$ cm ($n = 23$), the median time to vaginal delivery was 1 hour and 14 minutes (range from 27 minutes to 6 hours and 10 minutes). For ITU stations lower than $+2$ cm ($n = 15$), the median time was 27 minutes (range from 2 minutes to 1 hour and 14 minutes).

Correlation with digital vaginal examination

There was a significant, but weak, positive correlation between head station assessed by digital examination and by ITU ($P < 0.001$, $r^2 = 0.24$; Figure 5). For a head station of $+1$ cm determined by digital vaginal examination, for example, head stations by ITU ranged from -1 to $+5.5$ cm. Significant, but weak correlations also existed between head station by digital vaginal examination and head direction ($P < 0.001$, $r^2 = 0.35$) and angle of descent ($P < 0.001$, $r^2 = 0.24$).

Table 1. Maternal, fetal, and birth characteristics of the study population

Maternal age	28.5 years (range 20.0–40.0 years; median 29.0 years)
Maternal height	166 cm (158–179 cm; median 165 cm)
Maternal weight	85.9 kg (68.0–129.0 kg; median 81.0 kg)
Body mass index	31.6 (23.7–48.5; median 30.1)
Ethnicity	Mixed/white (two Indian women, no African women)
Use of epidural analgesia	28% epidural, 50% combined spinal/epidural
Use of i.v. oxytocin to augment labour	94%
GA at delivery	39.8 weeks (37.3–41.7 weeks; median 39.9 weeks)
Birthweight	3430 g (2540–4310 g; median 3415 g)
Head circumference	34.9 cm (32.0–37.5 cm; median 35.0 cm)
Head position	o.p. $n = 3$; o.a. $n = 47$

GA, gestational age; o.a., occiput anterior; o.p. occiput posterior.

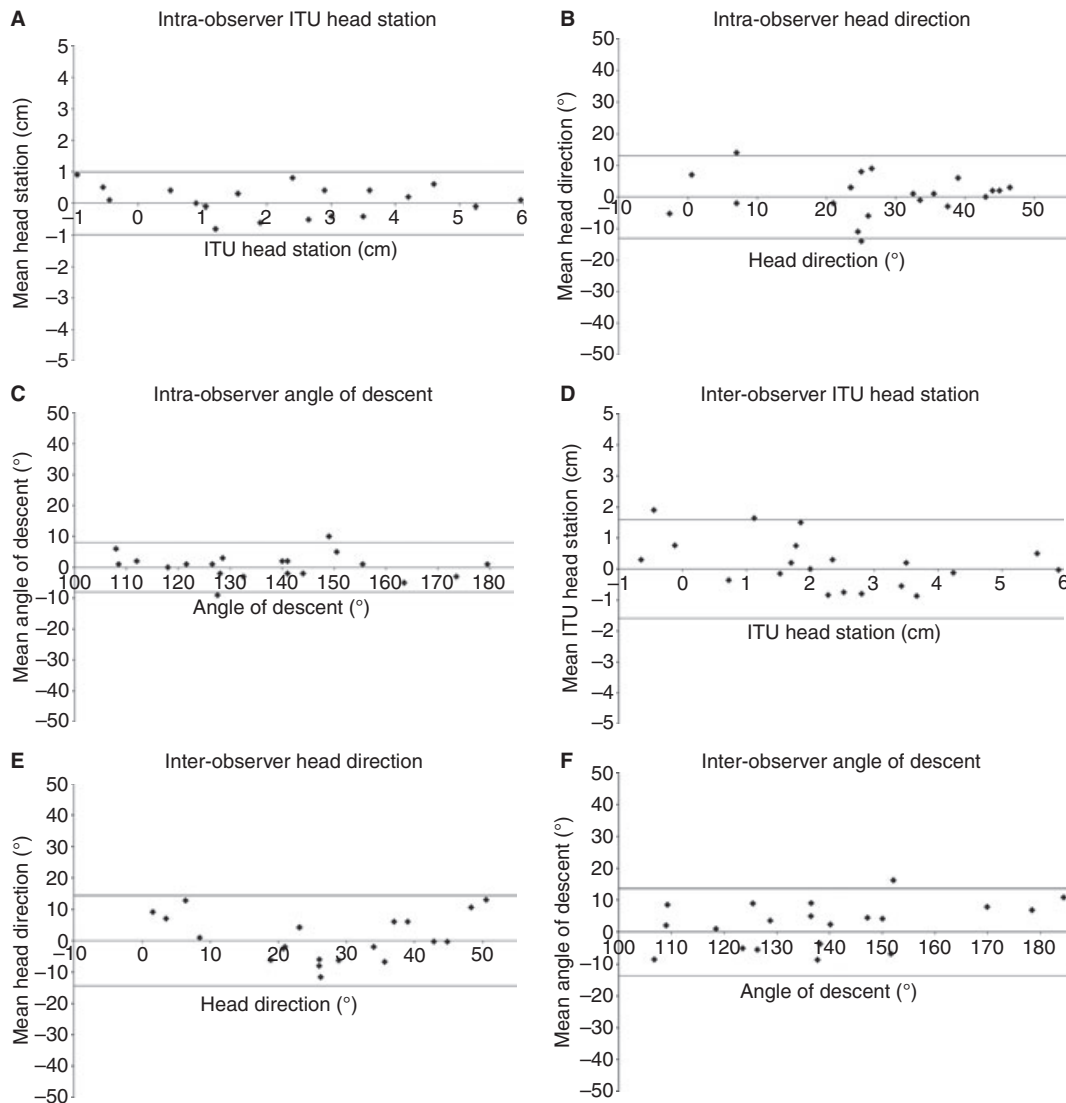


Figure 2. Repeatability of quantitative measurements of intrapartum translabial ultrasound (ITU). **A–C** Intra-observer and **D–F** interobserver variabilities of ITU head station, head direction, and angle of descent, respectively (with 95% limits of agreement).

Discussion

Ultrasound in labour has been used increasingly in recent years, initially to detect o.p. position.^{12,13} Dietz and co-workers established the pubic symphysis as a landmark for translabial ultrasound before labour, and examined its reproducibility.¹⁴ They also used translabial ultrasound before labour to measure head engagement, assessed pelvic organ mobility, and combined these measurements with patient history and other clinical parameters to predict mode of delivery.¹⁵ In 2006, we first described 'head direction' on ITU, combined three ITU parameters, and qualitatively correlated head station and head direction with the success of operative vaginal delivery.² Since then, several groups have published their experience with ITU to assess

and predict the course of labour,^{4–6,16} and the general principle has even been implemented in a commercial ultrasound system.¹⁷ As an alternative to cross-sectional ultrasound alone, at least two commercial systems exist that use either multiple ultrasonic positioning sensors without or magnetic field-positioning sensors with cross-sectional ultrasound imaging to track the fetal head during labour.^{18,19}

The relationship between the parameters of ITU, their repeatability, and their predictive values, and an analysis of birth mechanics as seen from ITU over the course of labour have not been described comprehensively. In the present study, we measured the reproducibility and correlation of ITU parameters, analysed the changes of ITU parameters during a naturally occurring contraction

Table 2. Repeatability of ITU parameters: there was good intra- and interobserver repeatability for ITU head station, angle of descent, and head direction

	Intra-observer variability				Interobserver variability			
	95% limits	Intraclass correlation			95% limits	Intraclass correlation		
		ICC*	95% CI	P		ICC*	95% CI	P
ITU station	±1 cm	0.97	0.92–0.99	<0.0001	±1.6 cm	0.86	0.67–0.94	<0.0001
Head direction	±13°	0.90	0.77–0.96	<0.0001	±14°	0.88	0.72–0.95	<0.0001
Angle of descent	±8°	0.98	0.95–0.99	<0.0001	±14°	0.95	0.88–0.98	<0.0001

*Intraclass correlation coefficient.

Table 3. Conversion of ITU-measured parameters: angle of descent and head station

Angle of descent (°)	ITU head station (in cm)
84	–3.0
90	–2.5
95	–2.0
100	–1.5
106	–1.0
111	–0.5
116	0.0
122	0.5
127	1.0
132	1.5
138	2.0
143	2.5
148	3.0
154	3.5
159	4.0
164	4.5
170	5.0

This table was calculated using the following formula, which was obtained by regression of head station over angle of descent: ITU head station (cm) = AoD (°) × 0.0937 – 10.911.

Table 4. Change in head station and head direction during a contraction, augmented by pushing, at different ITU-measured resting head stations

Women	Resting station (in cm)	Average head direction (°)	Delta station (cm)	Delta direction (°)
n = 4	–3.0 to –2.0	–16	2.5	11
n = 7	–1.9 to –1.0	–8	1.4	8
n = 10	–0.9 to 0.0	–2	1.3	10
n = 10	0.1–1.0	3	1.0	13
n = 9	1.1–2.0	9	0.7	7
n = 6	2.1–3.0	21	2.2	18
n = 4	>3.0	40	0.8	1

Table 5. Proportion of vaginal births depending on ITU parameters

ITU parameters	ITU ≥ +1.5 cm	Head direction > 20°	AoD > 120°
Vaginal birth?	12/13 (92%)	12/13 (92%)	25/27 (93%)

augmented by pushing, and describe their correlation with outcome.

We assessed repeatability in still images: comparing repeat measurements performed by one operator and between two operators, the ITU parameters head station, head direction, and AoD were clinically well reproducible. Very recently another group have reported a high level of reproducibility of ITU-measured AoD for images acquired successively, but in a blinded fashion, by two operators, and for still images analysed offline by nine operators.⁷

Using ITU, we found that, as the head descends along the curved birth canal, changes in head station and head direction during a contraction depend on the absolute head

station. At head stations between –3 and –2 cm, and again between +2 and +3 cm, there is greater head descent during a contraction with pushing than between –2 and +2 cm. Between stations +2 and +3 cm there is more ‘upward’ change during a contraction with pushing (on average +18°), following the direction of the birth canal at this station. However, the numbers in the two extreme groups (highest and lowest head station, respectively) were too small to assess for statistical analysis.

Intrapartum translabial ultrasound parameters recorded at the height of pushing correlate with birth outcome and interval to delivery. For an ITU station greater than +2.0 cm, a head direction >22°, or an angle of descent

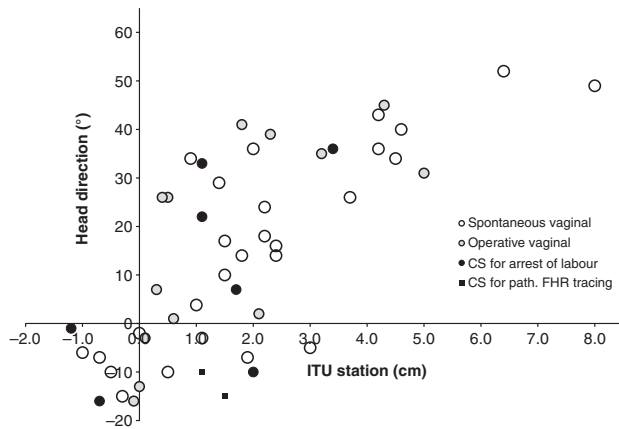


Figure 3. Intrapartum translabial ultrasound (ITU) parameters (head station and direction; one data point per fetus) and final mode of delivery. The likelihood of vaginal delivery increases with ITU head station. Empty and shaded circles indicate ITU head station and head direction for deliveries ending vaginally (either spontaneously or operatively). Filled circles and boxes indicate caesarean deliveries performed for arrest of labour or pathological fetal heart rate tracing, respectively.

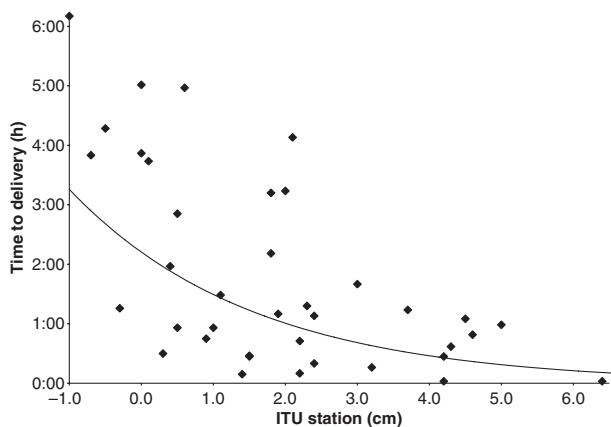


Figure 4. Time to delivery and intrapartum translabial ultrasound (ITU)-measured head station in vaginal deliveries (spontaneous or by vacuum extraction). The further down the head has descended, expressed by ITU head station, the shorter the interval between ITU measurement and delivery (time to delivery = $0.0919 - 0.391 \times \text{ITU station (in cm)}$, $r^2 = 0.38$, $P < 0.001$).

>135°, vaginal delivery (either spontaneous or operative) occurred in 33 of 34 (97%), 32 of 34 (94%), or 34 of 36 (94%) women, respectively. For an ITU head station above +2 cm the average interval to delivery was 2 hours and 30 minutes, but at +2 cm or below the interval was only 56 minutes.

Our group and others have shown that fetal head rotation can also be obtained easily using ITU in the transverse plane of the maternal pelvis. This view can be obtained either concurrently, using 3D or 4D sonography, or by rotating the transducer.^{5,20} We did not obtain this transverse view in all

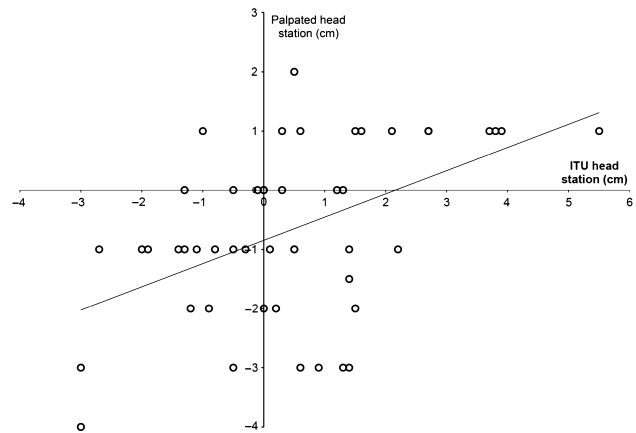


Figure 5. Head station estimated by digital vaginal examination versus head station measured by intrapartum translabial ultrasound (ITU). There was a weak correlation between the head station determined by digital vaginal examination and the sonographically measured head station [station by digital vaginal examination (in cm) = $0.3924 \times \text{ITU head station (in cm)} - 0.8467$, $r^2 = 0.24$, $P < 0.001$], with a wide spread of the stations determined by digital vaginal examination. For ITU head stations between 0 and +1, for example, the stations by vaginal examination ranged from -3 to +2.

deliveries in this study, but observed rotation of the fetal head in some cases (Video Clip S3). Inclusion of head rotation assessment in all fetuses, once the head has descended sufficiently, may provide additional information.

The clinical standard for the determination of head station relates the deepest bony part of the head to the level of the ischial spines.⁸ However, digital vaginal examination of head station and head position in labour is operator dependent, and is poorly reproducible.^{1,21–25} Our data suggest that ITU-measured head station may be more accurate than digital vaginal examination, which cannot quantify subtle differences in head station.

We only had data from three deliveries in o.p. position, but head direction seems to be different (downward or horizontal) from o.a. deliveries measured at comparable head stations.

When grouping ITU data by head station some of the groups were small (minimal $n = 4$). Larger studies should be undertaken to confirm the conclusions from our data. We assessed ITU parameters at rest and at the height of pushing in each subject, but only once during each delivery. Therefore, we had to extrapolate the course of vaginal birth progress from this cross-sectional data. A longitudinal study (several measurements during the same delivery) could confirm the pattern of changes that we found.

Conclusion

Vaginal birth is a natural process, but occasionally requires urgent medical intervention to avoid harm to the labouring

woman and her unborn child. Our new data may improve our understanding of normal and abnormal labour, enable objective measurement of birth progress, and provide a more scientific basis for assessing labour. We speculate that ITU may reduce the risks of assisted labour, and that it might even avoid unnecessary caesarean deliveries.

Disclosure of interests

None for all authors.

Contribution to authorship

BT designed the study, performed the data analysis, and wrote the manuscript. TB contributed to the study design, was involved in the clinical care of the women, performed the data collection, and contributed to the data analysis and writing of the article. FC contributed to the study design, data analysis, and writing of the article. WH contributed to study design, data analysis, and writing of the article. All authors saw and approved the final version of this article. BT is the corresponding author, had full access to all the data, and has the final responsibility for the decision to submit the article.

Details of ethics approval

The Institutional Review Board approved the study and informed consent was obtained from every woman. Institutional Review Board: Charité, Ethikkommission, Ethikausschuss 2 am Campus Virchow-Klinikum, Antragsnummer EA2/113/09; date of approval, 15 December 2009 and 5 January 2010.

Funding

None.

Acknowledgements

None.

Supporting information

The following supplementary materials are available for this article:

Figure S1. Correlation of ITU-measured head station and angle of descent.

Video Clip S1. Change of head direction during a contraction augmented by pushing as seen with intrapartum translabial ultrasound (ITU): In the upper part of the birth canal and down to head station of +2 cm, head direction varies, but mostly changes from down to horizontal.

Video Clip S2. Change of head direction between head stations +2 cm and +3 cm: There is a greater change of head direction during a contraction (on average plus 18°).

Video Clip S3. Head rotation on intrapartum translabial ultrasound (ITU): When the head has descended suffi-

ciently, head rotation may provide additional information and confirmation of normal birth progress; in some cases rotation of the fetal head can be observed.

Additional Supporting Information may be found in the online version of this article.

Please note: Wiley-Blackwell are not responsible for the content or functionality of any supporting information supplied by the authors. Any queries (other than missing material) should be directed to the corresponding author. ■

References

- 1 Akmal S, Kametas N, Tsoi E, Hargreaves C, Nicolaides KH. Comparison of transvaginal digital examination with intrapartum sonography to determine fetal head position before instrumental delivery. *Ultrasound Obstet Gynecol* 2003;21:437–40.
- 2 Henrich W, Dudenhausen J, Fuchs I, Kamena A, Tutschek B. Intrapartum translabial ultrasound (ITU): sonographic landmarks and correlation with successful vacuum extraction. *Ultrasound Obstet Gynecol* 2006;28:753–60.
- 3 Barbera AF, Imani F, Becker T, Lezotte DC, Hobbins JC. Anatomic relationship between the pubic symphysis and ischial spines and its clinical significance in the assessment of fetal head engagement and station during labor. *Ultrasound Obstet Gynecol* 2009;33:320–5.
- 4 Barbera AF, Pombar X, Perugino G, Lezotte DC, Hobbins JC. A new method to assess fetal head descent in labor with transperineal ultrasound. *Ultrasound Obstet Gynecol* 2009;33:313–9.
- 5 Ghi T, Farina A, Pedrazzi A, Rizzo N, Pelusi G, Pilu G. Diagnosis of station and rotation of the fetal head in the second stage of labor with intrapartum translabial ultrasound. *Ultrasound Obstet Gynecol* 2009;33:331–6.
- 6 Kalache KD, Duckelmann AM, Michaelis SA, Lange J, Cichon G, Dudenhausen JW. Transperineal ultrasound imaging in prolonged second stage of labor with occipitoanterior presenting fetuses: how well does the 'angle of progression' predict the mode of delivery? *Ultrasound Obstet Gynecol* 2009;33:326–30.
- 7 Duckelmann AM, Bamberg C, Michaelis SA, Lange J, Nonnenmacher A, Dudenhausen JW, *et al.* Measurement of fetal head descent using the 'angle of progression' on transperineal ultrasound imaging is reliable regardless of fetal head station or ultrasound expertise. *Ultrasound Obstet Gynecol* 2010;35:216–22.
- 8 Cunningham FG, Gant NF, Leveno KJ, Gilstrap LC, Hauth JC, Wenstrom KD. Mechanisms of normal labor. In: Cunningham FG, MacDonald PC, Gant NF, Leveno KJ, Gilstrap LC, Hankins GDV, Clark SL, editors. *Williams Obstetrics*, 21th edn. New York, NY: McGraw Hill; 2001. pp. 291–307.
- 9 Salomon N, Siedentopf J, Grieser C, Henrich W. 3D reconstruction of the female pelvis to estimate the distance between the infrapubic line and the plane of ischial spines. *J Perinat Med* 2009;37(s1):296.
- 10 Bland JM, Altman DG. Statistical methods for assessing agreement between two methods of clinical measurement. *Lancet* 1986;8:1.
- 11 Bland JM, Altman DG. Applying the right statistics: analyses of measurement studies. *Ultrasound Obstet Gynecol* 2003;22:85–93.
- 12 Sherer DM. Intrapartum ultrasound. *Ultrasound Obstet Gynecol* 2007;30:123–39.
- 13 Yeo L, Romero R. Sonographic evaluation in the second stage of labor to improve the assessment of labor progress and its outcome. *Ultrasound Obstet Gynecol* 2009;33:253–8.

- 14 Dietz HP, Lanzacone V. Measuring engagement of the fetal head: validity and reproducibility of a new ultrasound technique. *Ultrasound Obstet Gynecol* 2005;25:165–8.
- 15 Dietz HP, Lanzacone V, Simpson JM. Predicting operative delivery. *Ultrasound Obstet Gynecol* 2006;27:409–15.
- 16 Lau WL, Leung WC, Chin R. What is the best transperineal ultrasound parameter for predicting success of vacuum extraction? *Ultrasound Obstet Gynecol* 2009;33:735; author reply 6.
- 17 Ghi T, Salomon N, Henrich W, Pili G. The benefits of sonography-based volume computer aided Display labor (SonoVCADlabor) during second stage labor. GE Healthcare Product description, 2009.
- 18 Sharf Y, Farine D, Batzalel M, Megel Y, Shenhav M, Jaffa A, et al. Continuous monitoring of cervical dilatation and fetal head station during labor. *Med Eng Phys* 2007;29:61–71.
- 19 Nizard J, Haberman S, Paltiel Y, Gonen R, Ohel G, Le Bourthe Y, et al. Determination of fetal head station and position during labor: a new technique that combines ultrasound and a position-tracking system. *Am J Obstet Gynecol* 2009;200:404.e1–5.
- 20 Fuchs I, Tutschek B, Henrich W. Visualization of the fetal fontanels and skull sutures by three-dimensional translabial ultrasound during the second stage of labor. *Ultrasound Obstet Gynecol* 2008;31:484–6.
- 21 Akmal S, Tsoi E, Kametas N, Howard R, Nicolaides KH. Intrapartum sonography to determine fetal head position. *J Matern Fetal Neonatal Med* 2002;12:172–7.
- 22 Buchmann E, Libhaber E. Interobserver agreement in intrapartum estimation of fetal head station. *Int J Gynaecol Obstet* 2008;101:285–9.
- 23 Dupuis O, Ruimark S, Corinne D, Simone T, Andre D, Rene-Charles R. Fetal head position during the second stage of labor: comparison of digital vaginal examination and transabdominal ultrasonographic examination. *Eur J Obstet Gynecol Reprod Biol* 2005;1:123.
- 24 Sherer DM, Miodovnik M, Bradley KS, Langer O. Intrapartum fetal head position II: comparison between transvaginal digital examination and transabdominal ultrasound assessment during the second stage of labor. *Ultrasound Obstet Gynecol* 2002;19:264–8.
- 25 Sherer DM, Miodovnik M, Bradley KS, Langer O. Intrapartum fetal head position I: comparison between transvaginal digital examination and transabdominal ultrasound assessment during the active stage of labor. *Ultrasound Obstet Gynecol* 2002;19:258–63.