

Evidence-based guidelines for the management of abnormally invasive placenta recommendations from the International Society for Abnormally Invasive Placenta

Sally L. Collins, MD, PhD; Bahrin Alemdar, MD; Heleen J. van Beekhuizen, MD; Charline Bertholdt, MD; Thorsten Braun, MD; Pavel Calda, MD; Pierre Delorme, MD; Johannes J. Duvekot, MD; Lene Gronbeck, MD; Gilles Kayem, MD; Jens Langhoff-Roos, MD; Louis Marcellin, MD; Pasquale Martinelli, MD; Olivier Morel, MD; Mina Mhallem, MD; Maddalena Morlando, MD; Lone N. Noergaard, MD; Andreas Nonnenmacher, MD; Petra Pateisky, MD; Philippe Petit, MD; Marcus J. Rijken, MD; Mariola Ropacka-Lesiak, MD; Dietmar Schlembach, MD; Loïc Sentilhes, MD; Vedran Stefanovic, MD; Gita Strindfors, MD; Boris Tutschek, MD; Siri Vangen, MD; Alexander Weichert, MD; Katharina Weizsäcker, MD; Frederic Chantraine, MD; on behalf of the International Society for Abnormally Invasive Placenta (IS-AIP)

The worldwide incidence of abnormally invasive placenta is rapidly rising, following the trend of increasing cesarean delivery. It is a heterogeneous condition and has a high maternal morbidity and mortality rate, presenting specific intrapartum challenges. Its rarity makes developing individual expertise difficult for the majority of clinicians. The International Society for Abnormally Invasive Placenta aims to improve clinicians' understanding and skills in managing this difficult condition. By pooling knowledge, experience, and expertise gained within a variety of different healthcare systems, the Society seeks to improve the outcomes for women with abnormally invasive placenta globally.

The recommendations presented herewith were reached using a modified Delphi technique and are based on the best available evidence. The evidence base for each is presented using a formal grading system. The topics chosen address the most pertinent questions regarding intrapartum management of abnormally invasive placenta with respect to clinically relevant outcomes, including the following: definition of a center of excellence; requirement for antenatal hospitalization; antenatal optimization of hemoglobin; gestational age for delivery; antenatal corticosteroid administration; use of preoperative cystoscopy, ureteric stents, and prophylactic pelvic arterial balloon catheters; maternal position for surgery; type of skin incision; position of the uterine incision; use of interoperative ultrasound; prophylactic administration of oxytocin; optimal method for intraoperative diagnosis; use of expectant management; adjuvant therapies for expectant management; use of local surgical resection; type of hysterectomy; use of delayed hysterectomy; intraoperative measures to treat life-threatening hemorrhage; and fertility after conservative management.

Key words: abnormally invasive placenta, accreta, guideline, increta, morbidly adherent placenta, percreta, placenta, placenta accreta spectrum

From the Nuffield Department of Women's and Reproductive Health (Dr Collins), University of Oxford, Oxford, UK; The Fetal Medicine Unit (Dr Collins), John Radcliffe Hospital, Oxford, UK; Department of Obstetrics and Gynecology (Drs Alemdar and Strindfors), South General Hospital, Stockholm, Sweden; Department of Gynaecological Oncology (Dr van Beekhuizen), Erasmus Medical Center, Rotterdam, Netherlands; Centre Hospitalier Régional Universitaire de Nancy (Drs Bertholdt and Morel), Université de Lorraine, France; Departments of Obstetrics and Division of Experimental Obstetrics (Drs Braun, Nonnenmacher, Weichert, and Weizsäcker), Charité Universitätsmedizin Berlin, corporate member of Freie Universität Berlin, Humboldt-Universität zu Berlin, and Berlin Institute of Health, Campus Virchow-Klinikum and Campus Charité Mitte, Berlin, Germany; Department of Obstetrics and Gynecology (Dr Calda), General Faculty Hospital, Charles University, Prague, Czech Republic; Port-Royal Maternity Unit (Dr Delorme), Cochin Hospital, Paris-Descartes University, DHU Risk and Pregnancy, Assistance Publique-Hôpitaux de Paris, Paris, France; Department of Obstetrics and Gynecology (Dr Duvekot), Erasmus Medical Center Rotterdam, Rotterdam, Netherlands; Department of Obstetrics (Drs Gronbeck, Langhoff-Roos and Noergaard), Rigshospitalet, University of Copenhagen, Denmark; Department of Obstetrics and Gynecology (Dr Kayem), Hôpital Trousseau, Assistance Publique des Hôpitaux de Paris, Sorbonne University, Paris, France; Department of Gynecology Obstetrics II and Reproductive Medicine (Dr Marcellin), Hôpitaux Universitaires Paris Centre, Hôpital Cochin, APHP; Sorbonne Paris Cité, Université Paris Descartes, Faculté de Médecine, Paris, France; Department of Neuroscience (Drs Martinelli and Morlando), Reproductive Sciences and Dentistry, University of Naples Federico II, Naples, Italy; Department of Obstetrics (Dr Mhallem), Cliniques Universitaires Saint-Luc, Brussels, Belgium; Department of Women, Children and of General and Specialized Surgery (Dr Morlando), University "Luigi Vanvitelli", Naples, Italy; Department of Obstetrics and Gynecology (Dr Pateisky), Division of Obstetrics and Feto-Maternal Medicine, Medical University of Vienna, Vienna, Austria; Department of Obstetrics and Gynecology (Drs Petit and Chantraine), CHR Citadelle, University of Liege, Liege, Belgium; Vrouw & Baby (Dr Rijken), University Medical Centre Utrecht, Utrecht University, Utrecht, Netherlands; Department of Perinatology and Gynecology (Dr Ropacka-Lesiak), University of Medical Sciences, Poznan, Poland; Vivantes Network for Health (Schlembach), Clinicum Neukoelln, Clinic for Obstetric Medicine, Berlin, Germany; Department of Obstetrics and Gynecology (Dr Sentilhes), Hôpital Pellegrin, CHU de Bordeaux, Bordeaux, France; Department of Obstetrics and Gynecology (Dr Stefanovic), Fetomaternal Medical Center, Helsinki University Hospital and University of Helsinki, Finland; Prenatal Zurich (Dr Tutschek), Zürich, Switzerland, and Heinrich Heine University, Düsseldorf, Germany; Division of Obstetrics and Gynaecology (Dr Vangen), Norwegian National Advisory Unit on Women's Health, Oslo University Hospital, Rikshospitalet and Institute of Clinical Medicine, University of Oslo, Oslo, Norway.

Received Nov. 29, 2018; revised Feb. 13, 2019; accepted Feb. 27, 2019.

The authors report no conflict of interest.

Corresponding author: Sally L. Collins, MD, PhD. sally.collins@wrh.ox.ac.uk

0002-9378/\$36.00 • © 2019 Elsevier Inc. All rights reserved. • <https://doi.org/10.1016/j.ajog.2019.02.054>



Click Supplemental Materials under article title in Contents at ajog.org

Introduction

Abnormally invasive placenta (AIP), also called placenta accreta spectrum disorder (PAS), describes the clinical situation in which a placenta does not separate spontaneously at delivery and cannot be removed without causing abnormal and potentially life-threatening bleeding.^{1,2} There is increasing epidemiological evidence demonstrating that the incidence of AIP is rising worldwide.³ This is most likely due to the rising rates of cesarean delivery, which is the greatest single risk factor for AIP in subsequent pregnancies. Optimal management requires both accurate antenatal diagnosis and a robust perinatal management strategy. However, even with the rising incidence, AIP is still rare (0.79–3.11 per 1000 births after prior cesarean),⁴ and so defining an optimal management strategy remains extremely challenging. The literature contains a vast number of case reports, case series, and retrospective cohort studies looking at multiple management strategies; however, most studies are small, and many are methodologically flawed, limiting their utility. The situation is made even more difficult by the spectrum of presentations being presented in most studies as a binary outcome (“AIP” or “not AIP”), with varying diagnostic criteria and no attempted assessment of severity.²

The International Society for Abnormally Invasive Placenta (IS-AIP) (www.is-aip.org) evolved from the European Working group on AIP (EW-AIP) and currently consists of 42 clinicians and basic science researchers from 13 countries. At the 11th meeting of EW-AIP in Naples (2017), the IS-AIP constitution was formally agreed upon and the board elected. It was registered in Belgium on 12 October 2017 as a non-profit-making association. The Society has strict membership criteria and a full constitution (see www.is-aip.org).

The aim of the IS-AIP is to promote excellence in all aspects of healthcare relating to AIP, including research (clinical, epidemiological, and “wet lab” based), clinical diagnosis and management, education (including raising awareness within the general population and among healthcare providers,

especially with a view to prevention). The group as the EW-AIP has already published standardized descriptors to aid in the ultrasound diagnosis of AIP.⁵ This paper aims to generate an evidence-based recommendation for the intrapartum management of AIP using the unique, international composition of the IS-AIP to provide expert consensus recommendation where the evidence identified is weak, flawed, or absent.

Methods

The questions to be answered in this guideline were selected by a modified Delphi technique. The IS-AIP membership were all invited to suggest issues that they believed were pertinent to the management of AIP. These questions were then discussed in detail at an IS-AIP meeting in Prague (October 2016), with the final decision on inclusion being taken by a vote. All 21 questions addressed in this paper were unanimous agreed to be important by the IS-AIP membership.

The search and assessment of the published evidence was then undertaken by an individual IS-AIP member according to a predefined pro forma ([Supplementary Material](#)). In brief, this involved undertaking a full “systematic review” process for each topic, including formulating an appropriate question specific to AIP using the PICO framework⁶ and searching all relevant medical databases (PubMed, EMBASE, CINAHL, Cochrane Database, etc) and, where appropriate, some nonmedical databases (eg, Google). All searches for the 21 different topics were undertaken at various points during 2017. Full-text versions of all potential papers were then obtained, assessed for relevance, and critically appraised using the levels of evidence provided by the Centre for Evidence Based Medicine.⁷

All the completed pro formas detailing the formulated question, search strategy, results, and critical analysis for each topic were then sent to the entire membership for consideration of the search strategy used and the resulting literature retrieved. Where potential methodological issues were identified by another member (eg, problems with

search terms, usually relating to language differences; eg, searching only “ureteral” not “ureteric OR ureteral”), a second IS-AIP member repeated the search to ensure that no evidence had been missed. A few topics that revealed little high-quality evidence during the original 2017 search were searched again in 2018 to ensure that no further evidence had been published.

Once all the evidence had been identified, the recommendations were reached by a modified Delphi technique involving the entire membership of the IS-AIP. Each topic was discussed face-to-face by the membership, either at an IS-AIP meeting or using Web conferencing. A frank and open discussion concerning the available evidence ensured that, to the best of our ability, any personal bias regarding the evidence was removed and a fair interpretation of the data was recorded. Where possible, a recommendation was then drawn up from the evidence, taking into account the quality (level) of each piece of evidence. Where high quality evidence was scarce and level 5 “expert opinion” required, each topic was then discussed until a tentative consensus recommendation was reached. Each recommendation was then voted on and ratified only if it received support from the group. On completion of the process, all of the recommendations were then circulated to the entire membership once again to ensure that unanimous ratification of all recommendations remained.

Results

1. What constitutes “expertise” in management of AIP and/or defines a “center of excellence”?

Evidence for what constitutes an “expert” in the management of AIP is missing from the literature, despite opening the search strategy to non-medical databases such as Google. Therefore, the IS-AIP recommendation is based on a consensus opinion (level 5 evidence) and is:

An expert is a person with significant experience in AIP and a high level of knowledge and/or skills relating to the condition (Grade D recommendation).

Although there are multiple retrospective cohort studies demonstrating decreased maternal morbidity when women are cared for in self-defined “centers of excellence,”⁸⁻¹¹ there was no definitive evidence for what should constitute such a “center of excellence.” The IS-AIP recommendation is therefore based on a consensus opinion (level 5 evidence), and is summarized in Table 1.

This recommendation was reached independently of the recently published International Federation of Gynecology and Obstetrics (FIGO) consensus statement¹² and U.S. consensus panel recommendation¹³ but is in agreement with both.

2. Is there evidence of reduced morbidity if women antenatally diagnosed with AIP remain in the hospital until delivery?

Given the rarity of the condition, many physicians feel uncomfortable managing women diagnosed with AIP as outpatients, and therefore many are admitted to the hospital, often for several weeks if not months. There were no studies identified that specifically addressed the question of inpatient versus outpatient care for women antenatally diagnosed with AIP. As the majority of AIP cases are also placenta previa, an examination of the evidence available for placenta previa was also made. There were 5 publications reporting outcomes for expectant outpatient management of women with placenta previa (1 small randomized controlled trial¹⁴ and 4 retrospective cohort studies¹⁵⁻¹⁸).

The oldest publication, from 1984,¹⁷ presented data from a retrospective cohort of 38 women. The authors suggested significant improvement in neonatal morbidity and mortality for women with placenta previa who were managed as inpatients. However, there appeared to be significant recruitment bias, with the woman managed as outpatients being enrolled at significantly earlier gestations compared to those managed as inpatients (poor-quality cohort, level 4 evidence).

A subsequent small RCT by Wing et al¹⁴ reported the outcomes for 26

TABLE 1 International Society for Abnormally Invasive Placenta (IS-AIP) criteria for what constitutes a specialist center for AIP	
1.	A center that can provide a multidisciplinary team (MDT) with significant experience in managing abnormally invasive placenta (AIP) and that can provide antenatal diagnosis and preoperative planning. This team should be available 24 hours a day, 7 days a week, to ensure that expertise is available for emergency situations. This MDT should, as a minimum, include: <ul style="list-style-type: none"> • Imaging expert (fetal medicine specialist and/or radiologist) • Experienced obstetrician (often maternal-fetal medicine specialist) • Anesthesiologist with expertise in complex obstetric cases • Surgeon experienced with complex pelvic surgery (often a gynecological oncologist) • Urologist (with experience of open urological surgery especially ureteric re-implantation) • Neonatologist • Interventional radiologist^a
2.	There should be, <i>on site</i> , rapid access to the following in case of emergency: <ul style="list-style-type: none"> • Colorectal surgeon • Vascular surgeon • Hematologist
3.	Adult intensive care facilities available on site
4.	Gestational age—appropriate neonatal intensive care facilities
5.	Massive transfusion facilities
6.	Intraoperative blood salvage (cell salvage) services available ^b
<p>^a Although the IS-AIP do not recommend the routine use of prophylactic balloon occlusion, the availability of embolization in the event of massive hemorrhage remains important.; ^b Intraoperative blood salvage should be available for all elective procedures as a minimum.</p> <p><i>Collins. IS-AIP guideline for management of abnormally invasive placenta. Am J Obstet Gynecol 2019.</i></p>	

asymptomatic women with placenta previa managed at home compared with 27 who were hospitalized (low-quality RCT, level 2b evidence). The only significantly different outcome was length of hospital stay. Three retrospective cohort studies^{15,16,18} examined the outcomes for a total of 305 women (acceptable- and poor-quality cohorts, level 2b/4 evidence) and did not demonstrate any significant difference in either maternal or neonatal outcomes. All 3 studies concluded that in selected women with asymptomatic placenta previa, outpatient management was both safe and cost-effective. However, these were all retrospective cohort studies, and there may have been individual circumstances that biased the selection of care settings for the women involved. This evidence for outpatient management of placenta previa was taken into consideration when reaching the consensus recommendation for the management of AIP.

In conclusion, there is no evidence for antenatal hospitalization of asymptomatic women with antenatally diagnosed AIP, whether it is associated or not

associated with placenta previa. Therefore, the IS-AIP recommendation is extrapolated from the best available evidence for inpatient management of placenta previa¹⁴ (level 2b evidence) and is as follows:

Expectant outpatient management of women with AIP, even in the presence of placenta previa, is acceptable treatment, as long as the woman is asymptomatic and has been appropriately counseled (Grade C recommendation). However, adequate resources must be available to allow rapid return to the hospital (Grade D recommendation).

Symptomatic women (eg, those with bleeding, uterine contractions, or other obstetric complications) should be cared for according to local protocols and expertise (Grade D recommendation).

3. Is there evidence of reduced morbidity in women antenatally diagnosed with AIP if they receive iron supplementation to optimize hemoglobin levels?

In conditions with increased risk of severe bleeding at delivery, most

physicians will take steps antenatally to ensure that the woman's starting hemoglobin (Hb) level is as high as possible in an attempt to reduce morbidity. There was no evidence available for the benefit of antenatal optimization of Hb specifically for cases of AIP. A single study was identified that looked to identify determinants of blood loss at childbirth. This was a "nested cohort study" the participants for which had already been recruited to a community-based RCT of treatments for severe anemia in women from Zanzibar. This reported that women with Hb of <90 g/L at delivery were at increased risk for blood loss, both at the time of birth and in the immediate postpartum period, irrespective of mode of delivery¹⁹ (level 1b evidence). This study was taken into consideration, but it does not answer the original question posed; therefore, the IS-AIP recommendation is based on a consensus opinion (level 5 evidence) and is:

As soon as women are antenatally diagnosed with AIP, they should have their Hb level measured. If it is low (<110 g/L [11 g/dL] before 28 weeks' gestation or <105 g/L [10.5 g/dL] after 28 weeks' gestation), appropriate hematinic investigations should be undertaken and if indicated, iron supplementation (oral or intravenous) should be given to optimize their Hb level before surgery (Grade D recommendation).

This recommendation was reached independently but is in agreement with the UK Royal College of Obstetricians and Gynaecologists (RCOG) prevention and management of postpartum hemorrhage guideline (Green-top Guideline number 52)²⁰ and the recent FIGO consensus statement.¹²

4. At what gestation should women with antenatally diagnosed AIP be delivered?

Arranging an elective cesarean delivery earlier than usual may reduce the risk of an emergency delivery; however, the increased risks to the neonate from prematurity must also be considered. Six studies were found that reported maternal and neonatal outcomes for

different gestational ages at delivery in women with an antenatal diagnosis of AIP.^{9,21-25} All 6 were retrospective observational studies (level 4 evidence). None of the studies provided any robust evidence for the optimal gestational age for delivery for woman with AIP, to reduce maternal and neonatal morbidity while still minimizing the rate of unplanned, emergency delivery.

Robinson and Grobman²⁶ published a decision analysis in 2010 recommending that the optimal timing of delivery for women with placenta previa and ultrasound-based suspicion of AIP was 34 weeks. Their aim was to define the gestation that balanced the risks of prematurity with the risk of emergency delivery. The flaw in their elegant model is that the risk of bleeding used to formulate the 9 models was based on 400 women with placenta previa only and not previa with AIP.

Therefore, although all these studies were taken into consideration, the IS-AIP recommendation is based on a consensus opinion (level 5 evidence) and is:

The timing of delivery should be tailored to each unique set of circumstances and based on the individual woman's risk of emergent delivery. To reduce the risk of neonatal morbidity, it is reasonable to continue expectant management until after 36+0 weeks' gestation for women with no previous history of preterm delivery (<36+0 weeks') and who are stable with no vaginal bleeding, preterm premature rupture of the membranes (PPROM), or uterine contractions suggestive of preterm labor (Grade D recommendation).

In the case of women with history of previous preterm birth, multiple episodes of small amounts of vaginal bleeding, a single episode of a significant amount of vaginal bleeding or PPROM, planned delivery at around 34+0 weeks' gestation should be considered given the increased risk of emergent delivery (Grade D recommendation).

5. Is there evidence of reduced mortality or morbidity in neonates if women with antenatally diagnosed AIP receive corticosteroids for delivery occurring after 34+0 weeks' gestation?

The issue of administration of corticosteroids for preterm delivery after 34+0 weeks' gestation is contentious. It is unclear whether AIP itself makes the neonate more likely to experience respiratory distress. No prospective RCT exists evaluating the influence of AIP per se on neonatal respiratory morbidity beside the normal influence of prematurity when delivered between 34+0 and 37+0 weeks' gestation. One retrospective case series (level 4 evidence) of histopathologically diagnosed AIP compared the neonatal outcomes between antenatally diagnosed AIP and AIP cases diagnosed intrapartum.²⁵ Although there was no significant difference between the gestation at delivery (33.9 vs 34.7 weeks; $P = .34$) for the 2 groups, those women who were antenatally diagnosed were more likely to have received antenatal steroids (65% vs 16%; $P < .001$), yet still demonstrated a higher rate of admission to the neonatal intensive care unit (86% vs 60%; $P = .005$) and longer neonatal hospital stays (11 vs 7 days; $P = .006$). Interpretation of this dataset is difficult with regard to the specific question, as there are likely to be considerable confounding factors.

There was no evidence available that the presence of AIP itself increases neonatal respiratory morbidity or mortality if the scheduled delivery takes place between 34+0 and 37+0 weeks' gestation. Therefore, the IS-AIP recommendation for antenatal glucocorticoid treatment to induce fetal lung maturation for a scheduled delivery after 34+0 weeks' gestation is based on consensus opinion (level 5 evidence) and is as follows:

An individualized approach for antenatal steroid administration should be employed, based on the current local guidelines for the specific gestation at delivery, irrespective of the suspicion or diagnosis of AIP (Grade D recommendation).

6. Does routine preoperative cystoscopy improve the accuracy of antenatal diagnosis of AIP and/or reduce maternal morbidity in women with antenatally diagnosed AIP?

Preoperative cystoscopy to assess for bladder wall involvement is recommended by many operators; others argue that it adds no useful information while increasing the time in the operating room and the risks of infection and lower urinary tract trauma. No RCTs were found examining the efficacy of preoperative cystoscopy for the intrapartum management of AIP. One case series presented 12 patients with AIP and gross hematuria (level 4 evidence) who underwent preoperative cystoscopy.²⁷ The authors reported that the procedure did not help to establish a preoperative diagnosis in any patient, and concluded that cystoscopy had minimal diagnostic value.

The evidence that cystoscopic findings, even in the presence of gross hematuria, do not correlate to the level of bladder involvement was taken into account; however, given the poor quality of the study, the recommendation is supported by consensus opinion (level 5 evidence).

The IS-AIP does not recommend undertaking routine preoperative cystoscopy. If preoperative cystoscopy is performed for insertion of ureteric stents, the appearance of the bladder should not change the (imaging-based) plan of management (Grade D recommendation).

7. Does routine ureteric stent placement reduce maternal morbidity in cases of antenatally diagnosed AIP?

Ureteric stents may aid identification of the ureter and prevent inadvertent transection or ligation at hysterectomy; however, insertion has its own risks, such as urinary tract perforation and infection. One retrospective cohort study²⁸ (level 2b evidence) of 57 cases of suspected AIP and 19 undiagnosed cases reported on ureteric stenting and unintentional urinary tract injury. Ureteric stenting was attempted in 25 of the suspected cases. The stent placement was achieved bilaterally in 17 of 25 cases (68%), on only 1 side in 4 of 25 cases (16%), and on neither side in 4 of 25 cases (16%). Women with bilateral ureteral stents had a lower incidence of early

morbidity compared with women without stents (3/17 [18%] vs 22/40 [55%], $P = .018$). A nonsignificant reduction in ureteric injury was observed (0% vs 7%).

A systematic review of 49 case series and case reports (level 3a evidence), including the above cohort study, attempted to examine the efficacy of approaches aimed at minimizing urinary tract injuries in AIP.²⁹ Of the 292 women with AIP, whether or not ureteric stents were successfully placed was reported for 90 cases only. No details were available on the number in whom stent placement was attempted but unsuccessful. The risk of urinary tract injury was significantly lower in the group with ureteric stents in situ (2/35 [6%]) compared to those who were known not to have stents (18/55 [33%]; $P = .01$).

Neither study provided robust evidence regarding the severity of AIP that most benefited from stent placement; therefore the recommendation is also supported by consensus opinion (level 5 evidence) and is:

Placement of ureteric stents may be beneficial in preventing ureteric injury and early morbidity (Grade B recommendation). However, given the potential risks associated with stent placement, the evidence is not strong enough to recommend routine placement of ureteric stents for all suspected cases of AIP. The benefit from ureteric stents is probably limited to cases of percreta with significant invasion where hysterectomy is likely to be highly complex (Grade D recommendation).

8. Does routine insertion of prophylactic balloon catheters into the pelvic vasculature reduce maternal morbidity in cases of antenatally diagnosed AIP?

A main management objective for AIP is reduction of blood loss. Endovascular balloon occlusion of the pelvic circulation has been proposed as a method of achieving this. Given the aberrant blood supply often seen in AIP as a result of the extensive neovascularization, however, occluding some of the pelvic vessels might exacerbate bleeding from the collateral circulation. Therefore, the

benefits of arterial occlusion may not outweigh the associated risks of vessel rupture and thromboembolism.

A systematic review has recently been published looking at endovascular interventional modalities for hemorrhage control in AIP.³⁰ This included both prophylactic arterial balloon occlusion of different vessels, including the abdominal aorta, and pelvic vasculature embolization either alone or together. Only 16 of the 69 included studies were controlled, with the remaining being low-quality cohort, case series, or case studies. The heterogeneity of the studies was reported by the authors to be significant (review level 2a/3a evidence). All grades of AIP (accreta/increta/percreta) were grouped together for the meta-analysis with no differentiation in severity, with some studies including only balloon occlusion and others using vascular embolization as well. The authors concluded that “endovascular intervention is effective in controlling hemorrhage in abnormal placentation deliveries.”

One small RCT (level 1b evidence)³¹ was found that had been included in the systematic review.³⁰ This randomized 27 women with AIP and showed no difference in the number of packed red blood cell (RBC) units transfused for women who underwent placement of balloon catheters in the iliac arteries compared to those who did not, or any other reduction in morbidity. This RCT, however, also reported that 15% of the women with balloon catheters experienced an interventional radiology–related complication.

The IS-AIP considered the findings of both these 2 studies. The RCT is a much smaller data set, but is more methodologically rigorous (level 1b evidence). The systematic review, albeit larger, is very heterogeneous, includes data of very low quality, and may be open to significant bias (level 2a/3a evidence). Therefore, taking into account these 2 studies, the IS-AIP recommendation is as follows:

The effect of prophylactic arterial balloon catheters on bleeding and morbidity among women with a prenatal diagnosis of AIP has yet to be confirmed. Significant adverse events have been

reported from this procedure. Larger, prospective, appropriately controlled studies are needed to demonstrate both the safety and efficacy of prophylactic balloon occlusion. Given this, the IS-AIP cannot recommend routine use of prophylactic pelvic arterial balloon catheters for all cases of suspected AIP (Grade B recommendation).

This recommendation was reached independently of the recently published FIGO consensus statement¹² but is in agreement with it.

9. Is there an optimal maternal position for surgical delivery of women with antenatally diagnosed AIP?

Some operators suggest that women should be placed in the lithotomy position to aid assessment of vaginal blood loss and to facilitate manipulation of the cervix during hysterectomy. However, prolonged periods of time in stirrups may lead to compartment syndrome and obstetric neuropraxia. There are no publications that specifically address the question of maternal position for surgery for women with AIP. Therefore, the IS-AIP recommendation is based on consensus opinion (level 5 evidence) and is:

When hysterectomy is either planned or likely, the woman should be placed in a position in which the vagina is accessible (such as lithotomy or legs straight on the operating table but parted) to facilitate manipulation of the cervix, if required to assist the hysterectomy. This will also allow easier assessment of any blood lost vaginally (Grade D recommendation).

10. Does routine use of vertical midline incision instead of a transverse incision reduce maternal morbidity in cases of antenatally diagnosed AIP?

Many operators advise routine use of a vertical skin incision to facilitate access to the fundus and pelvic walls. However, a transverse incision may heal faster and reduce the risk of incisional hernia, as well as being more cosmetically pleasing for the woman. No studies were found comparing either maternal or fetal outcomes for different skin incisions. In the

few publications that mention the type of skin incision, a vertical midline incision appears to be used most frequently and is often anecdotally recommended. Other transverse incisions, such as Pfannenstiel and Maylard, have been reported and are recommended based on both esthetic considerations and the potential for a reduction in postsurgical complications. Given the lack of evidence, the IS-AIP recommendation is based on consensus opinion (level 5 evidence) and is:

There is no evidence of benefit for routine use of a vertical midline incision for all cases of antenatally diagnosed AIP. The decision regarding which type of skin incision is used should be made by the operating team. The location of the placenta, degree of invasion suspected, likelihood of intraoperative complications, maternal body habitus, gestational age, and preference of the operating surgeon/obstetrician should all be taken into consideration (Grade D recommendation).

11. Does making a uterine incision in the upper segment to avoid transecting the placenta reduce maternal morbidity in cases of antenatally diagnosed AIP?

One of the main surgical strategies in AIP is making the uterine incision away from the placental bed, often in the fundus. However, gaining access to the fundus may require a larger skin incision. One retrospective case series (level 4 evidence)³² reported blood loss after transverse fundal uterine incision to avoid the placenta in 34 women with placenta previa, 19 of whom had intraoperatively confirmed AIP. The average blood loss reported was 1370 g. There was no control group, and the severity of AIP was not reported, yet the authors conclude that this blood loss “compares favorably with the volume lost during a routine transverse lower segment section performed in patients without placenta previa or accreta.” It is not possible to draw any firm conclusion from this study; therefore the IS-AIP recommendation is based on expert consensus (level 5 evidence) and is as follows:

Avoiding placental transection when making the uterine incision is essential if

AIP is clearly evident on opening the abdomen, and is reasonable for women with antenatally suspected AIP but with no definite evidence seen at laparotomy, even if it means making an upper segment or fundal incision, as it is likely to reduce maternal blood loss from the placental bed (Grade D recommendation).

12. Does routine intraoperative ultrasound (US) to map the placental edges before uterine incision reduce maternal morbidity in cases of antenatally diagnosed AIP?

Several reports in the literature anecdotally recommend the use of intraoperative US, usually with the probe directly placed on the uterus protected by a sterile cover to enable the upper edge of the placenta to be identified. This is often mapped out with small, superficial diathermy marks. There is, however, a theoretical risk of introducing infection. No publications were found that address either the risks or benefits of intraoperative US scanning for placental localization in women with suspected AIP. One study by Al-Khan et al⁹ retrospectively analyzed patients before and after an institutional protocol for AIP management was introduced. In their protocol, intraoperative US for placental localization is performed, but the improvement in outcomes cannot be directly attributed to any individual measure. Therefore, the IS-AIP recommendation is based on a consensus of experts (level 5 evidence) and is as follows:

If the US scan is undertaken in an appropriately sterile manner, the small theoretical risk of introducing infection is outweighed by the benefit of ensuring the incision is made away from the placental bed. Therefore, intraoperative US of the exposed uterus should be used, where possible, to locate the placental edge and assist decision making regarding the uterine incision site (Grade D recommendation).

13. Does routine prophylactic administration of oxytocin after delivery of the infant reduce maternal morbidity in cases of antenatally diagnosed AIP?

There is evidence for the prophylactic administration of oxytocin after delivery at routine cesarean delivery to prevent PPH.³³ However, the use of routine oxytocin at cesarean delivery in cases of antenatally suspected AIP has not been addressed in any study. Therefore, the IS-AIP recommendation is based on a consensus of experts (level 5 evidence) and is as follows:

Prophylactic administration of oxytocin immediately after delivery increases contraction of the uterus, which could be helpful for the assessment of placental separation. If the whole placental bed is abnormally invasive, uterine contraction will not result in any placental separation. If, however, the placenta is only partially adherent or invasive, uterine contraction may cause some separation, leading to increased blood loss, which could prompt the surgeon to either forcibly remove the rest of the placenta or perform a more hurried hysterectomy. In light of this risk, the IS-AIP recommend that when AIP is suspected antenatally, prophylactic uterotonic agents should not be routinely given immediately after delivery of the infant. Instead a full assessment should be made in accordance with the intraoperative diagnosis recommendations (see next topic). Only if the placenta is removed, either fully or partially, or if there is already significant bleeding, should uterotonics be given (Grade D recommendation).

14. Is there an optimal method for intrapartum clinical diagnosis of AIP?

Although AIP can be suspected antenatally, ultimate confirmation occurs only when the placenta fails to separate after delivery of the infant. Attempts to forcibly remove an AIP may lead to catastrophic hemorrhage; hence reliable diagnostic signs are highly desirable. No evidence was found for which clinical diagnostic method best correlates with the gold-standard histopathological diagnosis; therefore, the IS-AIP recommendation is based on a consensus of experts (level 5 evidence) and is as follows:

The IS-AIP agree with the ACOG recommendation (level 5 evidence) that,

given the high risk of false-positive results with all methods of antenatal diagnosis, there must be robust intrapartum evidence that there is actually significant AIP before surgical treatment is commenced. Care must be taken, however, that major hemorrhage is not caused by inappropriate attempts to manually remove an AIP. The IS-AIP recommend the following methods for clinically diagnosing AIP:

Diagnosis of AIP after vaginal delivery:

The diagnosis of AIP should not be made if the placenta spontaneously separates and is delivered by maternal effort, controlled cord traction, or simple manual removal of an already separated placenta, even if there is a subsequent diagnosis of retained products of conception (RPOC). For the diagnosis of AIP, a manual removal of the placenta is required and at the time of manual exploration of the uterine cavity, in the opinion of a senior, experienced obstetrician, no plane of cleavage can be identified between the placenta and the myometrium. This can be for the entire placenta bed or just in “focal” areas. Major hemorrhage after piecemeal removal, removal of a “ragged placenta,” or discovery of subsequent RPOC is not sufficient to make the diagnosis of AIP (Grade D recommendation).

For diagnosis of AIP after laparotomy, a stepwise process should be followed:

Step 1: On opening the abdomen, the external surface of the uterus and the pelvis should be thoroughly inspected for frank signs of AIP, which include the following:

- *Uterus over the placental bed appears abnormal (can have a bluish/purple appearance) with obvious distension (a “placental bulge”) (Figure 1).*
- *Placental tissue is seen to have invaded through the surface of the uterus. This may or may not have penetrated the serosa (Figure 2).*

Note that care should be taken not to confuse this with a “uterine window,” which is a uterine scar dehiscence with the placenta visible directly underneath it. If it is a “uterine window,” the surrounding uterine tissue will appear normal (Figure 3).

- *Excessive, abnormal neo-vascularity is observed in the lower segment (particularly with vessels running cranio-caudally in the peritoneum) (Figure 4).*

If these are clearly seen, AIP can be diagnosed confidently without recourse to any further procedures (Grade D recommendation).

Step 2: If these are not seen, then the uterine incision should be made according to the level of suspicion for AIP (see separate topic above). If the incision has been placed such that the placenta is undisturbed, then gentle cord traction should be attempted. If traction on the umbilical cord causes the uterine wall to be visibly pulled inward in the direction of traction without any separation of the placenta (the “dimple” sign) and there is apparent contraction of the uterus separate from the placental bed, then AIP can be diagnosed (Grade D recommendation).

Step 3: If AIP has not been diagnosed by the previous 2 steps, then gentle digital exploration can be attempted to assess whether there is a plane of cleavage (following method for diagnosis of AIP described for vaginal delivery). Care must be taken to avoid causing hemorrhage (Grade D recommendation).

In an attempt to assess severity, the IS-AIP use the clinical grading score in Table 2. A version of this grading scale is also recommended by the recently published FIGO guidelines.³⁴

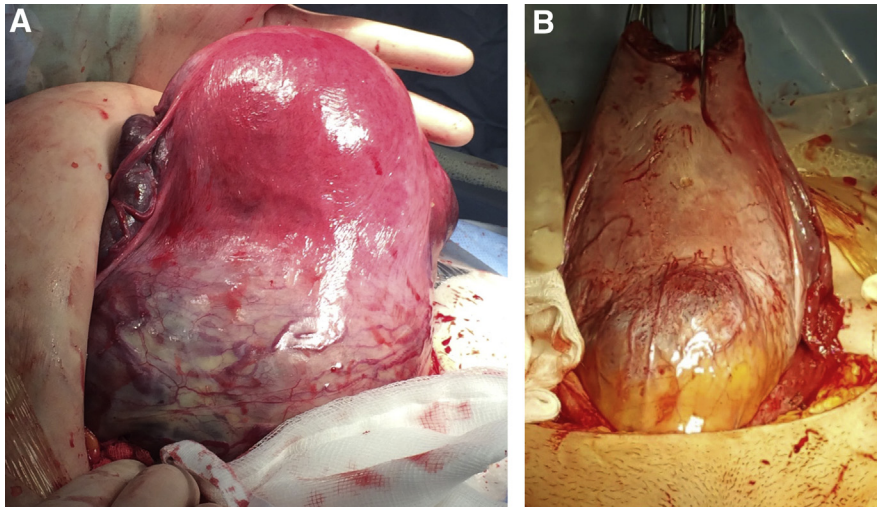
15. Is expectant management of clinically confirmed AIP effective, and does it reduce maternal morbidity when compared to surgical treatment options?

The “leaving the placenta in situ” approach, or expectant management, consists of leaving the entire placenta untouched and waiting for its complete resorption. Attempting forcible removal of the placenta significantly increases blood loss, hysterectomy rates, infection, and disseminated intravascular coagulation³⁵ (level 2b evidence).

Kutuk et al³⁶ recently published a retrospective cohort study comparing women undergoing hysterectomy without placental removal (n = 20),

FIGURE 1

Uterus over the placental bed appears abnormal (note the bluish/purple appearance) with obvious distension of the lower segment (a “placental bulge”)



Collins. IS-AIP guideline for management of abnormally invasive placenta. *Am J Obstet Gynecol* 2019.

expectant management (n = 15), and placental removal with uterus-conserving surgery (n = 11) (level 2b evidence). In 2 cases of percreta, treatment was planned to be uterus-conserving surgery, but management was changed to expectant when the surgeons found that the placenta had infiltrated the parametrium and the cervix. There was significantly lower blood loss in the expectantly managed

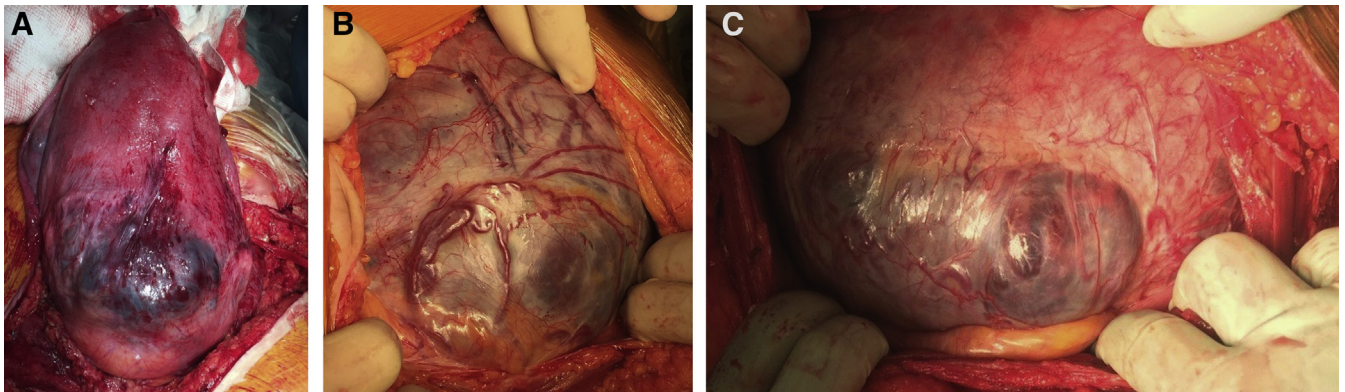
group (400 [250–2500] mL) than in both the hysterectomy (2000 [500–3500] mL; $P < .001$), and uterus-conserving surgery (3000 [1100–4000] mL; $P < .001$) groups. None of the expectantly managed women received blood products, compared with transfusions of 700 (200–2400) mL packed RBC in the hysterectomy group and 1200 (400–1800) mL in the uterus-conserving surgery group. Uterine

preservation rates were not significantly different between the expectantly managed women and those having uterus-conserving surgery (14/15 [93%] vs 33/37 [89%]; $P > .99$).

Most studies use avoidance of hysterectomy as the outcome measure of successful expectant management. The single largest case series of expectant management published to date is a multicenter retrospective study that included 167 cases of AIP in 40 teaching hospitals (level 2b evidence).³⁷ The overall success rate of uterine preservation was 78% (95% CI, 71–84%), with severe maternal morbidity reported in 10 cases (6%). An empty uterus was obtained spontaneously in 75% of cases, with additional hysteroscopic resection and/or curettage performed in 25%. One maternal death occurred as a direct result of methotrexate injection into the umbilical cord. As no hysterectomy specimens were available for histopathological confirmation, a criticism of this study is that some women may not actually have had an AIP. However, an experienced acoucher should be able to diagnose the vast majority of AIP cases clinically at laparotomy (see point 14), and subsequent histopathological findings from cases of “failed” expectant management suggest that the risk of misdiagnosis is very low. For this case series,³⁷ histopathological examination

FIGURE 2

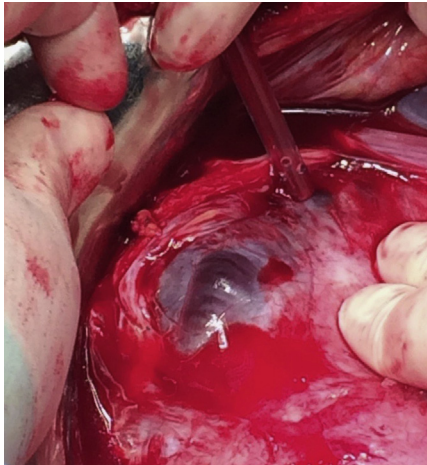
Placental tissue seen to have invaded through to the surface of the uterus. This may or may not have penetrated the serosa



Collins. IS-AIP guideline for management of abnormally invasive placenta. *Am J Obstet Gynecol* 2019.

FIGURE 3

A “uterine window” that is a uterine scar dehiscence with the placenta visible directly underneath it. Note that the surrounding uterine tissue appears normal and there is no abnormal neovascularity



Collins. IS-AIP guideline for management of abnormally invasive placenta. *Am J Obstet Gynecol* 2019.

confirmed the diagnosis of AIP in all the immediate hysterectomies (18/18) and all but 1 in the delayed hysterectomies (17/18).

Another smaller study of 36 women managed conservatively reported a success rate of 69%³⁸ (level 2b evidence). Three reviews of published case series report success rates of 85%,³⁹ 58%,⁴⁰

and 60%.⁴¹ Care must be taken in interpreting this, as these are not independent reviews, and many cases are included in all three studies (level 4 evidence).

The IS-AIP recommendation is as follows:

When expectant management is planned and AIP confirmed at delivery, forced manual removal of the placenta should not be attempted (Grade B recommendation).

Expectant management appears to be associated with less blood loss and lower transfusion requirements than both hysterectomy and uterus-conserving surgery and will be successful for between 60% and 93% of women, with the remainder undergoing hysterectomy, usually for secondary PPH or infection (Grade B recommendation). Therefore, this is an appropriate management strategy for women wishing to preserve their fertility and in cases where hysterectomy is considered to be at very high risk of surgical complications. If women choose this option, they must be appropriately counseled, including being informed that there is a 6% risk of severe maternal morbidity (Grade B recommendation).

16. If expectant management is undertaken for women with AIP, does the use of adjuvant therapies such as methotrexate and pelvic arterial embolization increase efficacy?

Methotrexate

Methotrexate has been suggested to accelerate placental resorption in cases of conservative management. There is no reliable evidence to support the use of methotrexate in cases of AIP left in situ. Only case reports and small case series with no control groups have been reported (level 4 evidence) therefore it is impossible to assess efficacy. Severe adverse effects such as pancytopenia and nephrotoxicity have been described with methotrexate.³⁷ One case of maternal death directly related to methotrexate was reported among the 21 patients who received methotrexate in the largest retrospective cohort of 167 women³⁷ (level 2b evidence).

The IS-AIP recommendation is therefore:

There is no evidence of benefit from the use of methotrexate when the placenta left in situ. As there is evidence for potential significant harm including maternal mortality, the IS-AIP do not recommend the use of methotrexate for conservative management of AIP (Grade B recommendation).

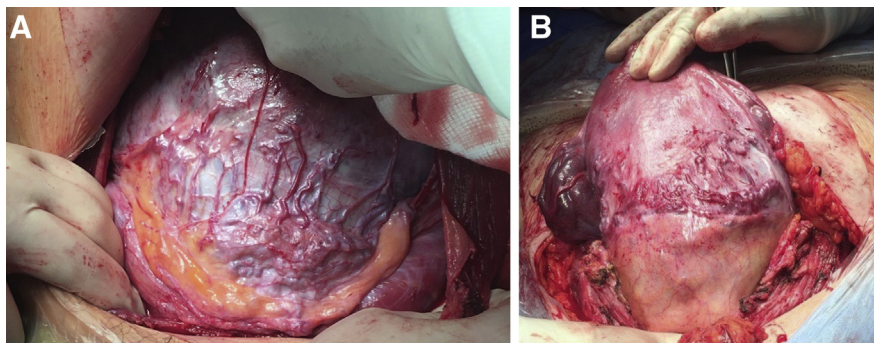
Pelvic arterial embolization

Prophylactic pelvic embolization has also been used to prevent severe PPH and secondary hysterectomy in cases of conservative management. However, the risks of morbidity from embolization may outweigh its potential benefit. A systematic review published in 2015, included 11 individual studies (mostly poor cohorts or case series) reporting on 177 cases of uterine artery embolization in women with AIP with planned conservative management⁴² (level 3a evidence). Hysterectomy was avoided in 159 of these women (90%). The review did not report maternal morbidity other than to say “all patients survived.”

A retrospective cohort study of 45 patients with AIP compared prophylactic artery uterine embolization to no embolization for women undergoing conservative management⁴³ (level 2b evidence). No difference was observed in blood loss, hysterectomy rates or incidence of massive transfusion. However, one patient in the embolization group had uterine necrosis requiring hysterectomy.

FIGURE 4

Excessive, abnormal neo-vascularity in the lower segment (note the vessels running cranio-caudally)



Collins. IS-AIP guideline for management of abnormally invasive placenta. *Am J Obstet Gynecol* 2019.

TABLE 2

A clinical grading system to assess the severity of an abnormally invasive placenta (AIP)^a**Grade Definition**

1	<i>At cesarean or vaginal delivery:</i> Complete placental separation at third stage. Placenta is delivered by maternal effort, controlled cord traction, or simple manual removal of an already-separated placenta. Not AIP.
2	<i>At cesarean delivery/laparotomy:</i> No placental tissue seen invaded through the serosal surface. Only partial separation with synthetic oxytocin and gentle CCT, MROP required for remaining tissue <i>and</i> parts of placenta thought to be abnormally adherent by a senior, experienced clinician. <i>At vaginal delivery:</i> MROP required <i>and</i> parts of placenta thought to be abnormally adherent by a senior, experienced clinician.
3	<i>At cesarean delivery/laparotomy:</i> No placental tissue seen invaded through the serosal surface of the uterus. The uterus over the placenta may appear bluish/purple and have an obvious “placental bulge.” No signs of any separation with synthetic oxytocin and gentle CCT results in the “dimple sign.” If MROP is attempted, the whole placental bed thought to be abnormally adherent by a senior, experienced clinician. <i>At vaginal delivery:</i> MROP required <i>and</i> the whole placental bed thought to be abnormally adherent by a senior, experienced clinician.
4	<i>At cesarean delivery/laparotomy:</i> Placental tissue seen to have invaded through the serosal surface of the uterus but <i>not</i> passing into any surrounding structures (including the posterior wall of the urinary bladder). A clear surgical plane can be identified between the bladder and uterus to allow atraumatic reflection of the urinary bladder at hysterectomy.
5	<i>At cesarean delivery/laparotomy:</i> Placental tissue seen to have invaded through the serosal surface of the uterus <i>and</i> invaded into the urinary bladder <i>only</i> (consequently, a clear surgical plane cannot be identified between the bladder and uterus to allow nontraumatic reflection of the urinary bladder at hysterectomy).
6	<i>At cesarean delivery/laparotomy:</i> Placental tissue seen to have invaded through the serosal surface of the uterus <i>and</i> invaded into the pelvic side wall or any organ other than the urinary bladder, with or without invasion into the urinary bladder.

AIP, abnormally invasive placenta; CCT, controlled cord traction; MROP, manual removal of placenta.

Note: For the purposes of this scale, “uterus” includes both the uterine body and the uterine cervix.

^a Adapted from: Collins SL, Stevenson GN, Al-Khan A, et al. Three-dimensional power Doppler ultrasonography for diagnosing abnormally invasive placenta and quantifying the risk. *Obstet Gynecol* 2015;126:645-53.

Collins. IS-AIP guideline for management of abnormally invasive placenta. *Am J Obstet Gynecol* 2019.

A report of a retrospective cohort of 12 patients having embolization to assist conservative management noted uterine necrosis requiring hysterectomy in 1 woman⁴⁴ (level 2b evidence). This study was included in the systematic review.⁴²

The IS-AIP recommendation is therefore:

There is no evidence for prophylactic uterine artery embolization increasing efficacy of conservative management, and 2 cases of uterine necrosis have been reported in 2 cohort studies (level 2b evidence). Therefore, the IS-AIP do not recommend prophylactic uterine artery embolization in women undergoing conservative management (Grade B recommendation). However, therapeutic embolization for postpartum hemorrhage in conservatively managed women may avoid hysterectomy (Grade D recommendation).

17. Does local surgical resection (uterus-conserving surgery) reduce maternal morbidity in women antenatally diagnosed with AIP when compared to other treatment

options including hysterectomy and conservative management?

Surgical removal of part of the myometrium where the placenta is abnormally attached (local surgical resection) has been proposed as a technique for managing AIP while conserving the uterus. Eleven original publications were found that reported on a variety of local resection techniques; 7 were retrospective cohort studies, 3 were prospective studies, and 1 was a review. Only 1 retrospective cohort study⁴⁵ (level 2b evidence), compared planned hysterectomy to local resection and found less bleeding in the local resection group measured as packed RBC transfusion (1.1 units compared with 2.2 units; $P < .05$). One retrospective cohort study⁴⁶ (level 2b evidence) compared a peripartum local resection technique known as the “Triple-P” procedure to conservative management leaving the placenta partly or entirely in the uterus. Blood loss was lower in the Triple-P group (1700 ± 950 mL vs 2170 ± 246 mL), but

this difference was not statistically significant ($P = .445$). The need for emergency peripartum hysterectomy was significantly lower in women undergoing the Triple-P procedure than in the control group (0/19 [0.0%] vs 3/11 [27.3%], $P = 0.045$).

Wei et al⁴⁷ published a retrospective cohort study of 96 patients with histopathologically confirmed AIP who were treated by local resection with ($n = 45$) or without ($n = 51$) a Foley catheter tied around the lower uterine segment to enhance hemostasis (level 2b evidence). Use of the Foley catheter appeared to reduce blood loss and possibly also the hysterectomy rate (0 vs 3).

Clausen et al⁴⁸ published a retrospective consecutive case series of placenta percreta treated with either hysterectomy or local resection (level 4 evidence). Of the 11 women requesting fertility preservation, 9 were successfully treated with local resection with a blood loss of 1300–6000 mL. The 8 women undergoing hysterectomy had a blood loss of 450–16,000 mL. The difference in

blood loss between the 2 treatments, however, does not reflect intention to treat. The 1 woman who had a 16,000-mL blood loss had requested fertility preservation, and local resection was attempted initially followed by a hysterectomy, as the placenta had invaded into the cervix and parametrium.

Kutuk et al³⁶ published a retrospective cohort study comparing women undergoing hysterectomy without placental removal (n = 20), expectant management (n = 15), and women who underwent placental removal and uterine conserving surgery (n = 11) (level 2b evidence) (see the topic on expectant management for further details).

In all of the other studies, the intended surgical procedure was local resection, and there was no comparator group.⁴⁹⁻⁵⁴ The success rates for avoiding hysterectomy ranged between 67% and 100%.

In 2014, Clausen et al published a review of 119 patients with placenta percreta stratified by mode of management⁴⁰ (level 3a evidence). In all, 17 cases reported were local resection with no secondary hysterectomies; 36 cases were conservatively managed, in 3 of which the patients underwent a planned delayed hysterectomy and 18 had emergency hysterectomies; and 66 had primary cesarean hysterectomies. Local resection was reported to be associated with a lower rate of complications including urinary tract injury, secondary hemorrhage, and infection. However, there was no information provided regarding how the choice for local resection was made.

The evidence available for the efficacy of local resection is complicated by selection bias and poor comparator groups, making interpretation of the results difficult. However, the IS-AIP recommendation based on the available evidence and supported by consensus opinion is as follows:

There is no evidence to demonstrate that routine local resection in all cases of AIP reduces maternal morbidity or mortality compared to other treatment methods. However, in appropriately selected cases, local resection appears to be reasonably successful (level 2b evidence), and may reduce blood loss and maternal morbidity

compared to hysterectomy (level 2b/4 evidence) and requirement for emergency hysterectomy compared with conservative management (level 3b evidence). Therefore, local resection should be considered in appropriately selected cases (Grade B recommendation).

There is, however, some evidence to suggest that attempting local resection may be detrimental in cases involving invasion into the uterine cervix and/or parametrium (level 4 evidence). Therefore, local resection should be considered only where there is no invasion into the parametrium and/or uterine cervix (Grade C recommendation).

The IS-AIP expert consensus of what constitutes an "appropriate case" for local resection is focal disease with an adherent/invasive area which is <50% of the anterior surface of the uterus (Grade D recommendation). More evidence is required to fully identify which women will most benefit from this management strategy.

18. Does performing a subtotal hysterectomy reduce maternal morbidity in women antenatally diagnosed with AIP when compared to total hysterectomy?

Subtotal, or supracervical, hysterectomy has been reported to be associated with lower maternal morbidity than total hysterectomy, particularly in pregnant women. Although several studies on AIP reported the actual numbers of subtotal and total hysterectomy performed in their cohorts, no evidence for the benefit of one type of hysterectomy compared to another was presented. Wright et al⁵⁵ reported on a retrospectively collected cohort of 4967 peripartum hysterectomies performed in the United States (level 2b evidence). AIP was the stated indication for 1789 (36%) of these hysterectomies. No subgroup analysis of the AIP cases was presented. For the overall dataset of all peripartum hysterectomies, total hysterectomy was associated with more bladder injuries (10.2% vs 7.2%, $P < .001$), an increased number of other operative injuries (10.4% vs 8.3%, $P = 0.02$), more gastrointestinal complications (7.9% vs.

6.3%, $P = .04$), and a longer hospital stay ($P < .001$). Subtotal hysterectomy was associated with more secondary operations (5.0% vs 3.6%, $P = .02$), higher rates of transfusions (52.4% vs 42.7%, $P < .001$), and a higher perioperative maternal death rate (1.4% vs 0.8%, $P = .04$).

Knight et al, on behalf of the UK Obstetric Surveillance System (UKOSS), examined all the peripartum hysterectomies occurring in the United Kingdom over a 12-month period⁵⁶ (level 2b evidence). For the 318 hysterectomies performed, there were no significant differences in outcomes between total and subtotal hysterectomy. In all, 119 of the hysterectomies were performed for AIP; these were more commonly total hysterectomies, but no subgroup analysis between the 2 methods was reported.

Another 6 small retrospective studies were identified (level 3b/4 evidence). Ogunniyi et al reported 32 cases of peripartum hysterectomy⁵⁷ and demonstrated that subtotal hysterectomy was associated with higher postoperative morbidity than total (55.6% vs 71.4%; $P < .01$). Roopnarinesingh et al reported 52 cases in a single center in Dublin.⁵⁸ They found that total hysterectomy was associated with a significantly higher transfusion rate (12.7 units vs 9.4 units; $P < .001$). Saeed et al reported on 39 cases from a single center in Pakistan⁵⁹ and found that total hysterectomy had a significantly higher number of postoperative complications than did subtotal hysterectomy.

D'Arpe et al reported on 51 cases from a single center in Italy⁶⁰; Daskalakis et al reported on 45 cases from a single center in Athens⁶¹; and Olamijulo et al reported on 34 cases from a single center in Nigeria.⁶² No significant differences in morbidity were found in these studies (level 4 evidence).

No information was available in any study regarding how the decision was made regarding the method of hysterectomy. Therefore, the evidence available is highly likely to be complicated by considerable selection bias, making interpretation of these results extremely difficult. For that reason, the IS-AIP

recommendation is also supported by consensus opinion (level 5 evidence):

There is no evidence to demonstrate that routine subtotal hysterectomy in all cases of AIP reduces maternal morbidity or mortality compared to total hysterectomy; in fact, the largest study published suggested that subtotal might be associated with a higher maternal mortality rate (level 2b evidence).

The type of hysterectomy performed, therefore, should be individualized on a case-by-case basis, taking into account the site and degree of invasion both suspected antenatally and found at laparotomy, amount of bleeding, stability of the woman, and the skills, experience and preference of the operating team (Grade C recommendation). In cases with cervical invasion, total hysterectomy should be performed (Grade D recommendation).

19. Does performing a planned delayed hysterectomy reduce maternal morbidity in women antenatally diagnosed with AIP when compared to hysterectomy at the time of cesarean delivery?

A planned delayed hysterectomy involves leaving the placenta untouched in the uterus at the time of delivery, with the intention of performing a hysterectomy at a later date (days to weeks) after the cesarean delivery. This is performed in an attempt to reduce morbidity from the hysterectomy, as the uterine perfusion reduces after delivery of the infant even with the placenta in situ. Only 1 retrospective study was identified that attempted to compare planned delayed hysterectomy with immediate hysterectomy.⁶³ However, all the immediate hysterectomy cases presented as emergencies without antenatal diagnosis and with signs of shock from hemorrhage. The delayed cases were all antenatally diagnosed and the women underwent delivery in a hemodynamically stable condition (poor-quality cohort, level 4 evidence).

This study was taken into consideration, but as it is methodologically flawed, the IS-AIP recommendation is based on a consensus opinion (level 5 evidence) and is as follows:

Given the evidence for the success of expectant management for AIP, the IS-AIP recommend that the surgical choice should be between immediate surgical management (hysterectomy or local resection) and expectant management. There is no evidence of benefit of planned delayed hysterectomy, and the potential complications of performing a second intentional surgical procedure in a stable patient outweigh the benefits (Grade D recommendation).

20. What are the most effective intraoperative measures to treat life-threatening massive hemorrhage in women with AIP, should it occur at the time of delivery?

Strategies for massive bleeding from AIP vary according to operator experience and resources available. We found no RCTs providing direct comparison of different intraoperative strategies to reduce blood loss in the event of life-threatening hemorrhage.

Pharmacological treatments

There were no publications that specifically addressed the question of the effectiveness of uterotonics or hemostatic/procoagulant agents as life-saving measures to treat massive hemorrhage directly attributable to AIP. Therefore, the IS-AIP recommendation is based on consensus opinion (level 5 evidence) and is as follows:

Uterotonics should be considered in accordance with local protocols whenever massive uterine bleeding occurs until either hemostasis is achieved or the uterus is removed. Hemostatic/procoagulant agents can also be used in accordance with local protocols where the surgeon believes they will be of benefit (Grade D recommendation).

The benefit of early administration of tranexamic acid in reducing maternal mortality has been proven in the WOMAN study. This is a large multicenter, double-blind, placebo-controlled RCT comparing tranexamic acid to placebo to prevent death from all causes of bleeding, including AIP and other morbidities⁶⁴ (level 1b evidence). Therefore, the IS-AIP recommendation for its use is as follows:

Tranexamic acid should be administered whenever massive hemorrhage occurs, preferably as soon as possible after onset of significant bleeding (Grade A recommendation).

Surgical treatments

Internal iliac artery ligation

Four retrospective studies were identified reporting a total of 105 cases of internal iliac artery ligation (IIAL) performed to reduce hemorrhage at deliveries complicated by AIP.⁶⁵⁻⁶⁸ Three of these were retrospective cases series of women undergoing IIAL, with no comparator group (level 4 evidence),^{65,66,68} and 1 was a retrospective cohort study comparing outcomes for women with AIP treated with or without IIAL, at the time of delivery (poor-quality cohort, level 4 evidence).⁶⁷ The authors concluded that IIAL did not contribute to a reduction in blood loss; however, as the indication for undertaking IIAL was not described, this study is highly likely to be confounded by selection bias. Consequently, it was not possible to appropriately evaluate the efficacy of IIAL for reducing blood loss.

Uterine devascularization

One retrospective study, from Verspyck et al,⁶⁹ reported immediate and long-term outcomes in 6 women undergoing surgical uterine devascularization at the time of cesarean delivery, followed by conservative management of their AIP (level 4 evidence). No conclusion can be drawn from this regarding the efficiency of the technique for hemorrhage control, but the study demonstrated that uterine devascularization appears to be a reasonably safe technique as long as it is not associated with ovarian artery ligation.

Uterine compression sutures

Compression sutures after extirpation of placenta were reported in 3 retrospective studies⁷⁰⁻⁷² including a total of 47 women. Shahin et al reported 26 cases of women who had had bilateral uterine artery ligation followed by insertion of a B-Lynch suture for major hemorrhage from AIP (level 4 evidence).⁷⁰ Two of the 26 women died. Shazly et al reported a

similar case series of 7 women with hemorrhage from AIP who underwent bilateral uterine artery ligation and then multiple compression suturing (level 4 evidence).⁷¹ The authors reported that the procedure was successful. For both these studies, it is impossible to assess the efficacy of compression sutures alone, as the treatment also involved arterial ligation. The absence of a control group makes it impossible to assess the efficiency of this technique to reduce blood loss. Hwu et al reported a case series of 14 women who had a vertical compression suture involving both the anterior and posterior uterine walls to control bleeding from the placental bed (level 4 evidence).⁷² One of these women was diagnosed with AIP. Again, there was no control group, making assessment of efficacy in reducing blood loss impossible.

Balloon tamponade

One retrospective study⁷³ compared first-line hysterectomy (17 women) and balloon tamponade (19 women). Women who were assessed to have >50% invasion of the axial plane of the uterus were treated with immediate hysterectomy. The remainder had a balloon tamponade after extirpation of placenta, with or without extra square compression sutures to the placental bed. Blood loss and transfusion amounts were significantly lower in the tamponade group ($P < .05$); however, the selection criteria used brings into question the appropriateness of the 2 groups (poor-quality cohort, level 4 evidence). Also, it was not clear whether the tamponade was used to prevent or to treat hemorrhage. Three retrospective studies looking at treatment for PPH have also reported that the presence of an AIP is associated with a higher failure rate of balloon tamponade (level 4 evidence).⁷⁴⁻⁷⁶

Pelvic tamponade

A variety of techniques have been described for pelvic tamponade in the case of persistent bleeding after hysterectomy. Ghourab et al⁷⁷ described 5 cases of pelvic packing with 10–12 dry abdominal swabs (level 4 evidence).

Dildy et al⁷⁸ described a case series spanning 38 years of pelvic packing using a variety of materials, including pillow cases, gauze sheets, plastic X-ray cassette drapes, and orthopedic stockings, filled with gauze rolls (level 4 evidence). Charoenkwan et al⁷⁹ reported a case series of 3 women treated with pelvic tamponade using a large-volume Bakri balloon (level 4 evidence). There were no maternal deaths in any of the 3 reports. No comment can be made on which technique provides the most effective tamponade.

In light of the quality and potentially conflicting evidence available, the IS-AIP recommendations for the surgical procedures to be used in case of massive hemorrhage are based mostly on a consensus of expert opinion (level 5 evidence) and are as follows:

If the woman is stable, the bleeding is not imminently life threatening, and a conservative approach was planned (either for maternal request or if hysterectomy is anticipated to be at very high risk of surgical complications), surgical uterus-conserving procedures should be attempted before resorting to hysterectomy. The simplest techniques with the lowest complications should be performed first (Grade D recommendation).

If the placenta has been removed, intrauterine tamponade (eg, balloon tamponade) should be the first-line management. If this fails, or the placenta remains in situ, uterine devascularization, with or without uterine compressive sutures, should be tried. Internal iliac artery ligation has the highest risk of postoperative complications and therefore should be performed only if the previous steps have failed to control the bleeding (Grade D recommendation).

If the woman is unstable or the bleeding is life threatening, treatment must be focused on the source of the blood loss; this will most often be the placental bed, so emergency hysterectomy should be performed as rapidly as possible. Vascular compression (common iliac arteries or aorta) can be used as a temporary measure to gain time to resuscitate the woman and to complete definitive treatment (Grade D recommendation).

In case of persistent pelvic bleeding following hysterectomy, internal iliac

artery ligation and/or pelvic tamponade should be considered. Pelvic tamponade should be performed with appropriate, sterile equipment such as large abdominal swabs and broad-spectrum antibiotics given while the packing remains in situ (Grade D recommendation).

21. What is the likelihood of a further pregnancy for women who have had an AIP and successful uterine conservation?

Counseling women requesting uterine conserving treatment of AIP requires knowledge of the evidence regarding the possibility of subsequent pregnancy and associated risk of recurrence of AIP. There are case reports⁸⁰⁻⁸⁴ (level 4 evidence), case series^{49,71,85,86} (level 4 evidence), case-controlled studies⁸⁷ (level 3b evidence), and cohort studies⁸⁸⁻⁹² (level 2b evidence) that clearly demonstrate preservation of fertility after successful conservative management of AIP. There are, however, no prospective or randomized studies.

In the largest cohort study, of 131 women who had successful conservative management of AIP, the authors reported that 27 women expressed a desire for a subsequent pregnancy. Of these women, 24 (89%) had 34 spontaneously conceived pregnancies (level 2b evidence).⁹⁰ Another retrospective observational study assessed 46 women who had successful conservative management of AIP⁹¹; 12 (86%) of the 14 patients desiring another pregnancy achieved a total of 15 pregnancies (level 2b evidence). The only other cohort study presenting outcomes for women desiring a subsequent pregnancy reported that 5 of 6 women (83%) achieved a successful pregnancy (level 2b evidence).⁸⁸ These studies included women who had received a multitude of additional treatments, including administration of methotrexate, embolization of uterine arteries, pelvic arterial ligation, hysteroscopic resection of retained tissues, and segmental excision of the uterus. No study addressed the effect that these different management strategies had on fertility preservation or what degree of placental adherence/

invasion each woman had prior to conservative management.

Two of the cohort studies also examined the recurrence rates for AIP. In the largest study,⁹⁰ AIP recurred in 6 (29%) of the 21 pregnancies that continued beyond 34 weeks' gestation and was associated with placenta previa in 4 cases (level 2b evidence). The other study reported that of the 9 patients who delivered after 35 weeks' gestation, 2 (22%) had recurrence of placenta accreta (level 2b evidence).⁹¹

There is considerable evidence demonstrating that women who have successful conservative management of AIP may go on to have a successful future pregnancy. What remains unclear is what effect different methods used for conservative management, such as arterial embolization or uterine resection, have on fertility rates, and what is impact the original degree of adherence or invasion. The IS-AIP recommendation is based on the available evidence supported by expert consensus (level 5 evidence) and is as follows:

Women wishing to preserve their fertility should be counseled that this is possible (Grade B recommendation). If conservative management is successful, the subsequent pregnancy rate is between 86% and 89% (Grade B recommendation). There is no evidence regarding the association of AIP degree (accreta/increta/percreta) or methods used for conservative management, and successful preservation of fertility.

Women wishing for fertility preservation should be managed by a team with appropriate resources and experience in conservative management according to that team's local protocols (Grade D recommendation). These women should be counseled that their risk of AIP in a subsequent pregnancy is between 22% and 29% (Grade B recommendation).

Discussion

There were few questions that could be answered using high-level evidence, and many of the recommendations are based on expert opinion. The paucity of appropriate evidence for the optimal management of this difficult and potentially life-threatening condition highlights the urgent need for large,

multicenter collaborations. However, until the international community comes to an agreement on robust clinical diagnostic criteria and appropriate stratification of severity for AIP, the issues with comparing studies and translating research results into clinical practice will remain. ■

ACKNOWLEDGMENTS

We would like to thank the past and present membership of the IS-AIP, formerly the European Working group on AIP (EW-AIP), for their dedication to this international collaboration aimed at improving the outcomes for women affected by AIP worldwide. We would like to thank all of the librarians who assisted with more than 30 searches, especially Ms. Nia Roberts, Librarian at University of Oxford. Pavel Calda is supported by a research grant (RVO-VFN64165) from the Ministry of Health of the Czech Republic.

REFERENCES

1. Chantraine F, Langhoff-Roos J. Abnormally invasive placenta—AIP. Awareness and proactive management is necessary. *Acta Obstet Gynecol Scand* 2013;92:369–71.
2. Jauniaux E, Collins S, Burton GJ. Placenta accreta spectrum: pathophysiology and evidence-based anatomy for prenatal ultrasound imaging. *Am J Obstet Gynecol* 2018;218:75–87.
3. Klar M, Michels KB. Cesarean section and placental disorders in subsequent pregnancies—a meta-analysis. *J Perinat Med* 2014;42:571–83.
4. Jauniaux E, Chantraine F, Silver RM, Langhoff-Roos J. Diagnosis FPA, Management Expert Consensus Panel. FIGO consensus guidelines on placenta accreta spectrum disorders: epidemiology. *Int J Gynaecol Obstet* 2018;140:265–73.
5. Collins SL, Ashcroft A, Braun T, et al. Proposal for standardized ultrasound descriptors of abnormally invasive placenta (AIP). *Ultrasound Obstet Gynecol* 2016;47:271–5.
6. Schardt C, Adams MB, Owens T, Keitz S, Fontelo P. Utilization of the PICO framework to improve searching PubMed for clinical questions. *BMC Med Inform Decis Mak* 2007;7:16.
7. Phillips B, Ball C, Sackett D, et al. Oxford Centre for Evidence-based Medicine—Levels of Evidence (March 2009). Available at: <https://www.cebm.net/2009/06/oxford-centre-evidence-based-medicine-levels-evidence-march-2009/>. Accessed April 16, 2019.
8. Smulian JC, Pascual AL, Hesham H, et al. Invasive placental disease: the impact of a multidisciplinary team approach to management. *J Matern Fetal Neonatal Med* 2017;30:1423–7.
9. Al-Khan A, Gupta V, Illsley NP, et al. Maternal and fetal outcomes in placenta accreta after

institution of team-managed care. *Reprod Sci* 2014;21:761–71.

10. Eller AG, Bennett MA, Sharshiner M, et al. Maternal morbidity in cases of placenta accreta managed by a multidisciplinary care team compared with standard obstetric care. *Obstet Gynecol* 2011;117:331–7.

11. Shamshirsaz AA, Fox KA, Salmanian B, et al. Maternal morbidity in patients with morbidly adherent placenta treated with and without a standardized multidisciplinary approach. *Am J Obstet Gynecol* 2015;212:218.e1-9.

12. Allen L, Jauniaux E, Hobson S, et al. FIGO consensus guidelines on placenta accreta spectrum disorders: nonconservative surgical management. *Int J Gynaecol Obstet* 2018;140:281–90.

13. Silver RM, Fox KA, Barton JR, et al. Center of excellence for placenta accreta. *Am J Obstet Gynecol* 2015;212:561–8.

14. Wing DA, Paul RH, Millar LK. Management of the symptomatic placenta previa: a randomized, controlled trial of inpatient versus outpatient expectant management. *Am J Obstet Gynecol* 1996;175:806–11.

15. Droste S, Keil K. Expectant management of placenta previa: cost-benefit analysis of outpatient treatment. *Am J Obstet Gynecol* 1994;170:1254–7.

16. Mouer JR. Placenta previa: antepartum conservative management, inpatient versus outpatient. *Am J Obstet Gynecol* 1994;170:1683–5; discussion 85–6.

17. D'Angelo LJ, Irwin LF. Conservative management of placenta previa: a cost-benefit analysis. *Am J Obstet Gynecol* 1984;149:320–6.

18. Love CD, Fernando KJ, Sargent L, Hughes RG. Major placenta praevia should not preclude out-patient management. *Eur J Obstet Gynecol Reprod Biol* 2004;117:24–9.

19. Kavle JA, Stoltzfus RJ, Witter F, Tielsch JM, Khalfan SS, Caulfield LE. Association between anaemia during pregnancy and blood loss at and after delivery among women with vaginal births in Pemba Island, Zanzibar, Tanzania. *J Health Popul Nutr* 2008;26:232–40.

20. Prevention and Management of Postpartum Haemorrhage: Green-top Guideline No. 52. *BJOG* 2017;124:e106–49.

21. Rac MW, Wells CE, Twickler DM, Moschos E, McIntire DD, Dashe JS. Placenta accreta and vaginal bleeding according to gestational age at delivery. *Obstet Gynecol* 2015;125:808–13.

22. Bowman ZS, Manuck TA, Eller AG, Simons M, Silver RM. Risk factors for unscheduled delivery in patients with placenta accreta. *Am J Obstet Gynecol* 2014;210:241.

23. Fishman SG, Chasen ST. Risk factors for emergent preterm delivery in women with placenta previa and ultrasound findings suspicious for placenta accreta. *J Perinat Med* 2011;39:693–6.

24. Pri-Paz S, Fuchs KM, Gaddipati S, Lu YS, Wright JD, Devine PC. Comparison between emergent and elective delivery in women with

- placenta accreta. *J Matern Fetal Neonatal Med* 2013;26:1007–11.
- 25.** Warshak CR, Ramos GA, Eskander R, et al. Effect of predelivery diagnosis in 99 consecutive cases of placenta accreta. *Obstet Gynecol* 2010;115:65–9.
- 26.** Robinson BK, Grobman WA. Effectiveness of timing strategies for delivery of individuals with placenta previa and accreta. *Obstet Gynecol* 2010;116:835–42.
- 27.** Washecka R, Behling A. Urologic complications of placenta percreta invading the urinary bladder: a case report and review of the literature. *Hawaii Med J* 2002;61:66–9.
- 28.** Eller AG, Porter TF, Soisson P, Silver RM. Optimal management strategies for placenta accreta. *Br J Obstet Gynaecol* 2009;116:648–54.
- 29.** Tam Tam KB, Dozier J, Martin JN Jr. Approaches to reduce urinary tract injury during management of placenta accreta, increta, and percreta: a systematic review. *J Matern Fetal Neonatal Med* 2012;25:329–34.
- 30.** Shahin Y, Pang CL. Endovascular interventional modalities for haemorrhage control in abnormal placental implantation deliveries: a systematic review and meta-analysis. *Eur Radiol* 2018;28:2713–26.
- 31.** Salim R, Chulski A, Romano S, Garmi G, Rudin M, Shalev E. Precesarean prophylactic balloon catheters for suspected placenta accreta: a randomized controlled trial. *Obstet Gynecol* 2015;126:1022–8.
- 32.** Kotsuji F, Nishijima K, Kurokawa T, et al. Transverse uterine fundal incision for placenta praevia with accreta, involving the entire anterior uterine wall: a case series. *BJOG* 2013;120:1144–9.
- 33.** Murphy DJ, MacGregor H, Munishankar B, McLeod G. A randomised controlled trial of oxytocin 5IU and placebo infusion versus oxytocin 5IU and 30IU infusion for the control of blood loss at elective caesarean section—pilot study. *ISRCTN 40302163*. *Eur J Obstet Gynecol Reprod Biol* 2009;142:30–3.
- 34.** Jauniaux E, Bhide A, Kennedy A, et al. FIGO consensus guidelines on placenta accreta spectrum disorders: prenatal diagnosis and screening. *Int J Gynaecol Obstet* 2018;140:274–80.
- 35.** Kayem G, Keita H. [Management of placenta previa and accreta]. *J Gynecol Obstet Biol Reprod (Paris)* 2014;43:1142–60.
- 36.** Kutuk MS, Ak M, Ozgun MT. Leaving the placenta in situ versus conservative and radical surgery in the treatment of placenta accreta spectrum disorders. *Int J Gynaecol Obstet* 2018;140:338–44.
- 37.** Sentilhes L, Ambroselli C, Kayem G, et al. Maternal outcome after conservative treatment of placenta accreta. *Obstet Gynecol* 2010;115:526–34.
- 38.** Miyakoshi K, Otani T, Kondoh E, et al. Retrospective multicenter study of leaving the placenta in situ for patients with placenta previa on a cesarean scar. *Int J Gynaecol Obstet* 2018;140:345–51.
- 39.** Timmermans S, van Hof AC, Duvekot JJ. Conservative management of abnormally invasive placentation. *Obstet Gynecol Surv* 2007;62:529–39.
- 40.** Clausen C, Lonn L, Langhoff-Roos J. Management of placenta percreta: a review of published cases. *Acta Obstet Gynecol Scand* 2014;93:138–43.
- 41.** Pather S, Strockyj S, Richards A, Campbell N, de Vries B, Ogle R. Maternal outcome after conservative management of placenta percreta at caesarean section: a report of three cases and a review of the literature. *Aust N Z J Obstet Gynaecol* 2014;54:84–7.
- 42.** Mei J, Wang Y, Zou B, et al. Systematic review of uterus-preserving treatment modalities for abnormally invasive placenta. *J Obstet Gynaecol* 2015;35:777–82.
- 43.** Pan Y, Zhou X, Yang Z, Cui S, De W, Sun L. Retrospective cohort study of prophylactic intraoperative uterine artery embolization for abnormally invasive placenta. *Int J Gynaecol Obstet* 2017;137:45–50.
- 44.** Bouvier A, Sentilhes L, Thouveny F, et al. Planned caesarean in the interventional radiology cath lab to enable immediate uterine artery embolization for the conservative treatment of placenta accreta. *Clin Radiol* 2012;67:1089–94.
- 45.** Kilicci C, Ozkaya E, Eser A, et al. Planned cesarean hysterectomy versus modified form of segmental resection in patients with placenta percreta. *J Matern Fetal Neonatal Med* 2017;1–6.
- 46.** Teixidor Vinas M, Belli AM, Arulkumaran S, Chandrharan E. Prevention of postpartum hemorrhage and hysterectomy in patients with morbidly adherent placenta: a cohort study comparing outcomes before and after introduction of the Triple-P procedure. *Ultrasound Obstet Gynecol* 2015;46:350–5.
- 47.** Wei Y, Cao Y, Yu Y, Wang Z. Evaluation of a modified "Triple-P" procedure in women with morbidly adherent placenta after previous caesarean section. *Arch Gynecol Obstet* 2017;296:737–43.
- 48.** Clausen C, Stensballe J, Albrechtsen CK, Hansen MA, Lonn L, Langhoff-Roos J. Balloon occlusion of the internal iliac arteries in the multidisciplinary management of placenta percreta. *Acta Obstet Gynecol Scand* 2013;92:386–91.
- 49.** Palacios Jaraquemada JM, Pesaresi M, Nassif JC, Hermosid S. Anterior placenta percreta: surgical approach, hemostasis and uterine repair. *Acta Obstet Gynecol Scand* 2004;83:738–44.
- 50.** Chandrharan E, Rao S, Belli AM, Arulkumaran S. The Triple-P procedure as a conservative surgical alternative to peripartum hysterectomy for placenta percreta. *Int J Gynaecol Obstet* 2012;117:191–4.
- 51.** Shabana A, Fawzy M, Refaie W. Conservative management of placenta percreta: a stepwise approach. *Arch Gynecol Obstet* 2015;291:993–8.
- 52.** Karaman E, Kulusari A, Cetin O, et al. Local resection may be a strong alternative to cesarean hysterectomy in conservative surgical management of placenta percreta: experiences from a tertiary hospital. *J Matern Fetal Neonatal Med* 2017;30:947–52.
- 53.** Barinov S, Tirskeya Y, Medyanikova I, Shamina I, Shirkun I. A new approach to fertility-preserving surgery in patients with placenta accreta. *J Matern Fetal Neonatal Med* 2017;1–5.
- 54.** Polat I, Yucel B, Gedikbasi A, Aslan H, Fendal A. The effectiveness of double incision technique in uterus preserving surgery for placenta percreta. *BMC Pregnancy Childbirth* 2017;17:129.
- 55.** Wright JD, Herzog TJ, Shah M, et al. Regionalization of care for obstetric hemorrhage and its effect on maternal mortality. *Obstet Gynecol* 2010;115:1194–200.
- 56.** Knight M, Ukoss. Peripartum hysterectomy in the UK: management and outcomes of the associated haemorrhage. *BJOG* 2007;114:1380–7.
- 57.** Ogunniyi SO, Esen UI. Obstetric hysterectomy in Ile-Ife, Nigeria. *Int J Gynaecol Obstet* 1990;32:23–7.
- 58.** Roopnarinesingh R, Fay L, McKenna P. A 27-year review of obstetric hysterectomy. *J Obstet Gynaecol* 2003;23:252–4.
- 59.** Saeed F, Khalid R, Khan A, Masheer S, Rizvi JH. Peripartum hysterectomy: a ten-year experience at a tertiary care hospital in a developing country. *Trop Doct* 2010;40:18–21.
- 60.** D'Arpe S, Franceschetti S, Corosu R, et al. Emergency peripartum hysterectomy in a tertiary teaching hospital: a 14-year review. *Arch Gynecol Obstet* 2015;291:841–7.
- 61.** Daskalakis G, Anastasakis E, Papantoniou N, Mesogitis S, Theodora M, Antsaklis A. Emergency obstetric hysterectomy. *Acta Obstet Gynecol Scand* 2007;86:223–7.
- 62.** Olamijulo JA, Abiara OE, Olaleye OO, Ogedengbe OK, Giwa-Osagie F, Oluwole OO. Emergency obstetric hysterectomy in a Nigerian teaching hospital: a ten-year review. *Nig Q J Hosp Med* 2013;23:69–74.
- 63.** Ansar A, Malik T, Shuja S, Khan S. Hysterectomy as a management option for morbidly adherent placenta. *J Coll Physicians Surg Pak* 2014;24:318–22.
- 64.** Collaborators WT. Effect of early tranexamic acid administration on mortality, hysterectomy, and other morbidities in women with postpartum haemorrhage (WOMAN): an international, randomised, double-blind, placebo-controlled trial. *Lancet* 2017;389:2105–16.
- 65.** Camuzcuoglu H, Toy H, Vural M, Yildiz F, Aydin H. Internal iliac artery ligation for severe postpartum hemorrhage and severe hemorrhage after postpartum hysterectomy. *J Obstet Gynaecol Res* 2010;36:538–43.
- 66.** Camuzcuoglu A, Vural M, Hilali NG, et al. Surgical management of 58 patients with placenta praevia percreta. *Wien Klin Wochenschr* 2016;128:360–6.
- 67.** Iwata A, Murayama Y, Itakura A, Baba K, Seki H, Takeda S. Limitations of internal iliac artery ligation for the reduction of intraoperative

hemorrhage during cesarean hysterectomy in cases of placenta previa accreta. *J Obstet Gynaecol Res* 2010;36:254–9.

68. Rauf M, Ebru C, Sevil E, Selim B. Conservative management of post-partum hemorrhage secondary to placenta previa-accreta with hypogastric artery ligation and endo-uterine hemostatic suture. *J Obstet Gynaecol Res* 2017;43:265–71.

69. Verspyck E, Resch B, Sergent F, Marpeau L. Surgical uterine devascularization for placenta accreta: immediate and long-term follow-up. *Acta Obstet Gynecol Scand* 2005;84:444–7.

70. Shahin AY, Farghaly TA, Mohamed SA, Shokry M, Abd-El-Aal DE, Youssef MA. Bilateral uterine artery ligation plus B-Lynch procedure for atonic postpartum hemorrhage with placenta accreta. *Int J Gynaecol Obstet* 2010;108:187–90.

71. Shazly SA, Badee AY, Ali MK. The use of multiple 8 compression suturing as a novel procedure to preserve fertility in patients with placenta accreta: case series. *Aust N Z J Obstet Gynaecol* 2012;52:395–9.

72. Hwu YM, Chen CP, Chen HS, Su TH. Parallel vertical compression sutures: a technique to control bleeding from placenta praevia or accreta during caesarean section. *BJOG* 2005;112:1420–3.

73. Pala S, Atilgan R, Baspinar M, et al. Comparison of results of Bakri balloon tamponade and caesarean hysterectomy in management of placenta accreta and increta: a retrospective study. *J Obstet Gynaecol* 2018;38:194–9.

74. Maher MA, Abdelaziz A. Comparison between two management protocols for postpartum hemorrhage during cesarean section in placenta previa: balloon protocol versus non-balloon protocol. *J Obstet Gynaecol Res* 2017;43:447–55.

75. Mathur M, Ng QJ, Tagore S. Use of Bakri balloon tamponade (BBT) for conservative management of postpartum haemorrhage: a tertiary referral centre case series. *J Obstet Gynaecol* 2018;38:66–70.

76. Cho HY, Park YW, Kim YH, Jung I, Kwon JY. Efficacy of intrauterine Bakri balloon tamponade in cesarean section for placenta previa patients. *PLoS One* 2015;10:e0134282.

77. Ghourab S, Al-Nuaim L, Al-Jabari A, et al. Abdomino-pelvic packing to control severe haemorrhage following caesarean hysterectomy. *J Obstet Gynaecol* 1999;19:155–8.

78. Dildy GA, Scott JR, Saffer CS, Belfort MA. An effective pressure pack for severe pelvic hemorrhage. *Obstet Gynecol* 2006;108:1222–6.

79. Charoenkwan K. Effective use of the Bakri postpartum balloon for posthysterectomy pelvic floor hemorrhage. *Am J Obstet Gynecol* 2014;210:586.

80. Kayem G, Pannier E, Goffinet F, Grange G, Cabrol D. Fertility after conservative treatment of placenta accreta. *Fertil Steril* 2002;78:637–8.

81. Tamate M, Matsuura M, Habata S, et al. Preservation of fertility and subsequent childbirth after methotrexate treatment of placenta percreta: a case report. *J Med Case Rep* 2015;9:232.

82. Mahendru R, Taneja BK, Malik S. Preservation of fertility following abnormally adherent placenta treated conservatively: a case report. *Cases J* 2009;2:9349.

83. Endo T, Hayashi T, Shimizu A, et al. Successful uterus-preserving surgery for treatment of chemotherapy-resistant placenta increta. *Gynecol Obstet Invest* 2010;69:112–5.

84. Alanis M, Hurst BS, Marshburn PB, Matthews ML. Conservative management of placenta increta with selective arterial embolization preserves future fertility and results in a

favorable outcome in subsequent pregnancies. *Fertil Steril* 2006;86:1514.

85. Hequet D, Morel O, Soyer P, Gayat E, Malartic C, Barranger E. Delayed hysteroscopic resection of retained tissues and uterine conservation after conservative treatment for placenta accreta. *Aust N Z J Obstet Gynaecol* 2013;53:580–3.

86. Legendre G, Zoulovits FJ, Kinn J, Senthiles L, Fernandez H. Conservative management of placenta accreta: hysteroscopic resection of retained tissues. *J Minim Invasive Gynecol* 2014;21:910–3.

87. Kabiri D, Hants Y, Shanwetter N, et al. Outcomes of subsequent pregnancies after conservative treatment for placenta accreta. *Int J Gynaecol Obstet* 2014;127:206–10.

88. Salomon LJ, deTayrac R, Castaigne-Meary V, et al. Fertility and pregnancy outcome following pelvic arterial embolization for severe post-partum haemorrhage. A cohort study. *Hum Reprod* 2003;18:849–52.

89. Ornan D, White R, Pollak J, Tal M. Pelvic embolization for intractable postpartum hemorrhage: long-term follow-up and implications for fertility. *Obstet Gynecol* 2003;102:904–10.

90. Sentilhes L, Kayem G, Ambroselli C, et al. Fertility and pregnancy outcomes following conservative treatment for placenta accreta. *Hum Reprod* 2010;25:2803–10.

91. Provansal M, Courbiere B, Agostini A, D'Ercole C, Boublil L, Bretelle F. Fertility and obstetric outcome after conservative management of placenta accreta. *Int J Gynaecol Obstet* 2010;109:147–50.

92. Bai Y, Luo X, Li Q, et al. High-intensity focused ultrasound treatment of placenta accreta after vaginal delivery: a preliminary study. *Ultrasound Obstet Gynecol* 2016;47:492–8.